

Patient Name Mrs. SUMITRA
Age/Sex 56YRS/F
Patient ID 011912280010
Specimen ID MolQ-B-2458-19

Client Name Civil Hospital Sec-10

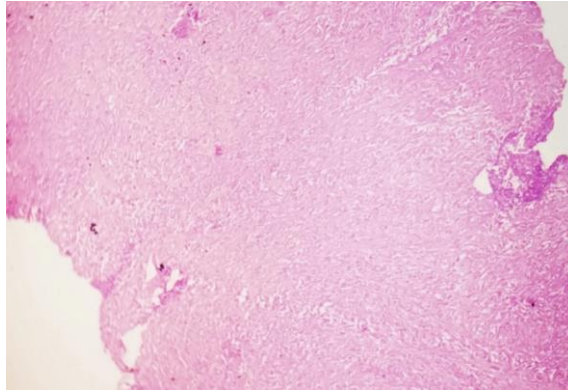
Specimen Received 28/12/2020
Specimen Type Tissue
Collection Date 28/12/2020
Report Date 01/01/2020

SURGICAL PATHOLOGY REPORT

Left Breast Lump

DIAGNOSIS

Kindly, co-relate with clinical and radiological findings.



SPECIMEN

Left Breast Lump

GROSS

Received one paraffin embedded block labeled with 3435/19.


Microscopy

Section examined shows stromal cells with inflammatory cells along with areas of necrosis. No ductal cells seen in block received.

Note : All biopsy specimen will be stored for 15 (fifteen) days, block and slides for 5 (five) years only from the time of receipt at the laboratory. No request, for any of the above, will be entertained after the due date.

Reference

- i) Rosai and Ackerman's Surgical Pathology.
- ii) Modern Surgical Pathology.


Gulshan Yadav, MD
Consultant Pathologist