

Patient Name Mrs. JYOTI
Age/Sex 27YRS/F
Patient ID 011912280004
Specimen ID MOLQ/B-2457/19

Client Name Civil Hospital Sec-10

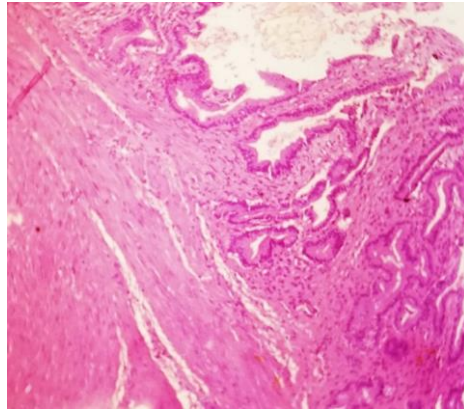
Specimen Received 28/12/19
Specimen Type Tissue
Collection Date 28/12/19
Report Date 31/12/19

SURGICAL PATHOLOGY REPORT

Gall Bladder

DIAGNOSIS

CHOLECYSTITIS AND CHOLELITHIASIS



SPECIMEN

Gall Bladder

GROSS

Received 7.5x2.9cm long gall bladder already cut open with stones. Wall thickness 0.9mm


Microscopy

Section examined shows ulcerative mucosa and Rokitansky-Aschoff sinuses (irregularly shaped tubular structures lined by cuboidal lining epithelium with round to oval nucleus) with fibrocollagenous tissue and inflammatory cells (lymphocytes).

Note : All biopsy specimen will be stored for 15 (fifteen) days, block and slides for 5 (five) years only from the time of receipt at the laboratory. No request, for any of the above, will be entertained after the due date.

Reference

- i) Rosai and Ackerman's Surgical Pathology.
- ii) Modern Surgical Pathology.


Gulshan Yadav, MD
Consultant Pathologist