

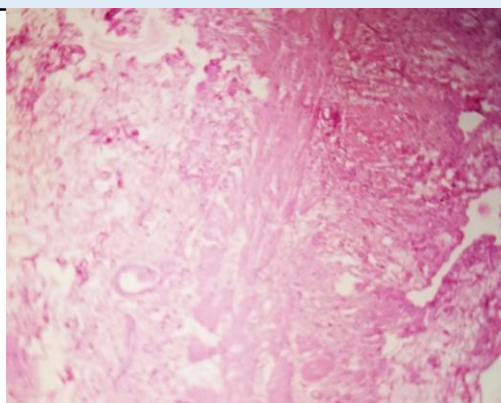
Patient Name	Mrs. SEEMA	Client Name	Path Star Diagnostic	Specimen Received	25/12/19
Age/Sex	37YRS/F			Specimen Type	Tissue
Patient ID	011912250208			Collection Date	25/12/19
Specimen ID	MOLQ/B-2441/19			Report Date	28/12/19

SURGICAL PATHOLOGY REPORT

Gall Bladder

DIAGNOSIS

CHOLECYSTITIS AND CHOLELITHIASIS.



SPECIMEN

Gall Bladder

GROSS

Received autolyzed 5.3x2.8cm long gall bladder. Cut section shows stones. wall thickness 0.3mm.

Microscopy

Section examined shows ulcerative mucosa and Rokitansky-Aschoff sinuses (irregularly shaped tubular structures lined by cuboidal lining epithelium with round to oval nucleus) with fibro collagenous tissue and inflammatory cells (lymphocytes).

Note : All biopsy specimen will be stored for 15 (fifteen) days, block and slides for 5 (five) years only from the time of receipt at the laboratory. No request, for any of the above, will be entertained after the due date.

Reference

- i) Rosai and Ackerman's Surgical Pathology.
- ii) Modern Surgical Pathology.

Gulshan Yadav, MD
Consultant Pathologist