

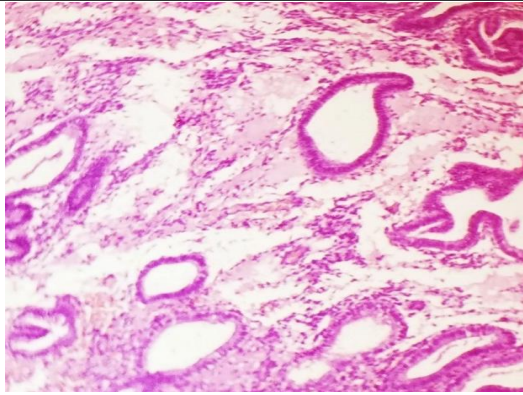
Patient Name	Ms. TASLEEMA	Client Name	Aggarwal Path Lab, NUH	Specimen Received	24/12/19
Age/Sex	30YRS/F			Specimen Type	Tissue
Patient ID	011912240154			Collection Date	24/12/19
Specimen ID	MOLQ/B-2434/19			Report Date	28/12/19

SURGICAL PATHOLOGY REPORT

Endometrium

DIAGNOSIS

DISORDERED PROLIFERATIVE PHASE



SPECIMEN

Endometrium

GROSS

Received multiple grayish white tissue piece.

Microscopy

Section examined shows small and tortous endometrial glands with cuboidal lining with small round nucleus. Stroma shows mononuclear inflammatory cells.

No granuloma seen. No malignant cells seen.

Note : All biopsy specimen will be stored for 15 (fifteen)days, block and slides for 5(five) years only from the time of receipt at the laboratory. No request ,for any of the above ,will be entertained after the due date.

Reference

- i) Rosai and Ackerman's Surgical Pathology.
- ii) Modern Surgical Pathology.

Gulshan Yadav, MD
Consultant Pathologist