

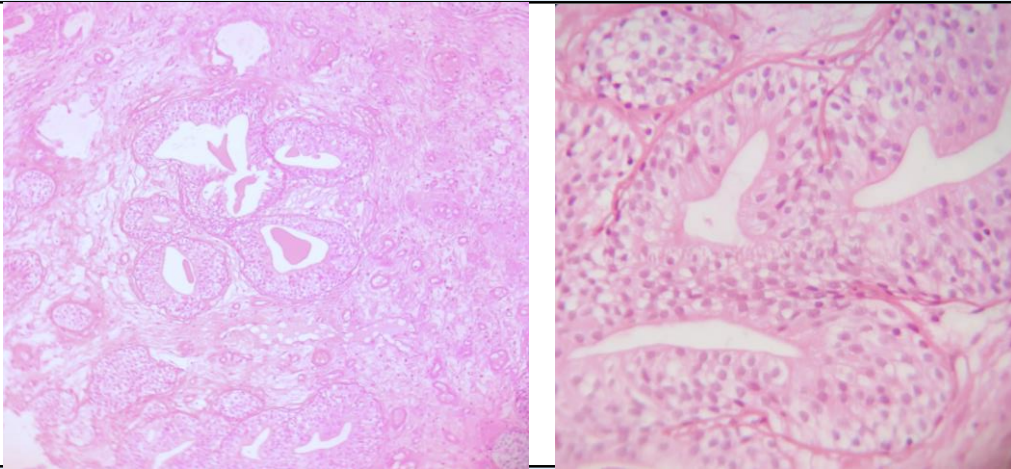
Patient Name	Mr. DEEPAK 45198	Client Name	Pushpanjali Hospital	Specimen Received	18-Dec-2019
Age/Sex	43 Years/Male		(Rewari)	Specimen Type	Tissue
Patient ID	011912180303			Collection Date	18-Dec-2019
Specimen ID	MOLQ/B-2394/19			Report Date	30-Dec-2019

SURGICAL PATHOLOGY REPORT

Prostatic Urethral Tumor

DIAGNOSIS

CLEAR CELL ADENOCARCINOMA, D/ D- UROTHELIAL CARCINOMA
ADVISED IHC FOR FURTHER CHARACTERIZATION



SPECIMEN

Prostatic Urethral Tumor

GROSS

Received multiple grayish white tissue piece, 1x2 cm in aggregate.

Microscopy

1. Sections show fragments of tissue with fibrocollagenous stroma and glands lined by glycogen-rich, cuboidal or hobnail cells with clear to eosinophilic cytoplasm.
2. These glandular cells have enlarged nuclei with mild pleomorphism, no prominent nucleoli seen. Stroma has prominent vasculature, inflammatory infiltrate, hyaline globules and psammoma bodies.
3. No papillae seen. No necrosis present.

Note : All biopsy specimen will be stored for 15 (fifteen) days, block and slides for 5 (five) years only from the time of receipt at the laboratory. No request, for any of the above, will be entertained after the due date.

Reference

- i) Rosai and Ackerman's Surgical Pathology.
- ii) Modern Surgical Pathology.

Gulshan Yadav, MD
Consultant Pathologist