

Patient Name Ms. PALO
Age/Sex 60YRS/F
Patient ID 011912210213
Specimen ID MOLQ/B-2424/19

Client Name Care Diagnostics Centre

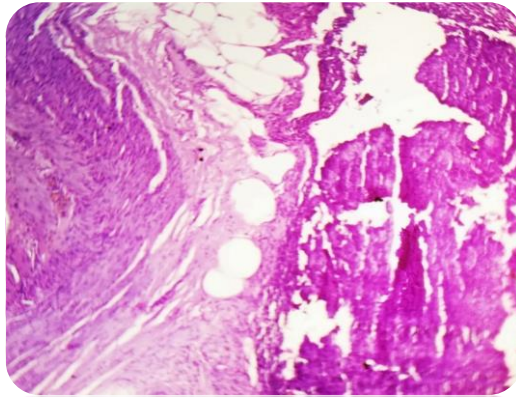
Specimen Received 21/12/19
Specimen Type Tissue
Collection Date 21/12/19
Report Date 25/12/19

SURGICAL PATHOLOGY REPORT

Appendix

DIAGNOSIS

ACUTE APPENDICITIS



SPECIMEN

Appendix

GROSS

Received 4x0.8cm long appendix with mesoappendix.
Cut section shows feco-lith.


Microscopy

Section examined shows lymphoid follicles with ulcerative mucosa. Deeper tissue shows inflammatory cells (polymorphs and lymphocytes). No granuloma seen. No malignant cells seen.

Note : All biopsy specimen will be stored for 15 (fifteen)days, block and slides for 5(five) years only from the time of receipt at the laboratory. No request ,for any of the above ,will be entertained after the due date.

Reference

- i) Rosai and Ackerman's Surgical Pathology.
- ii) Modern Surgical Pathology.


Gulshan Yadav, MD
Consultant Pathologist