

Patient Name Mrs. SEEMA
Age/Sex 40YRS/F
Patient ID 011912200214
Specimen ID MOLQ/B-2414/19

Client Name Family Health Point

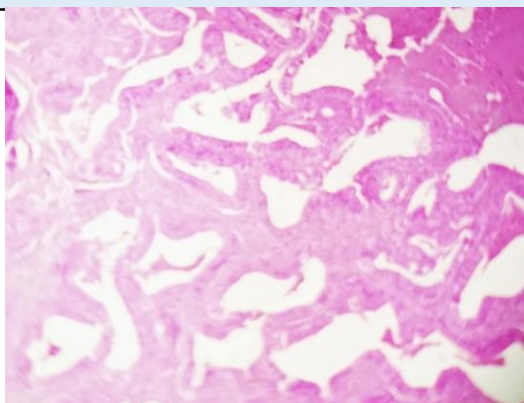
Specimen Received 20/12/19
Specimen Type Tissue
Collection Date 20/12/19
Report Date 24/12/19

SURGICAL PATHOLOGY REPORT

Gall Bladder

DIAGNOSIS

CHOLECYSTITIS AND CHOLELITHIASIS .



SPECIMEN

Gall Bladder

GROSS

Received 6x2.8cm long gall bladder. Cut section shows tiny stones.


Microscopy

Section examined shows ulcerative mucosa and Rokitansky-Aschoff sinuses (irregularly shaped tubular structures lined by cuboidal lining epithelium with round to oval nucleus) with fibrocollagenous tissue and inflammatory cells (lymphocytes).

Note : All biopsy specimen will be stored for 15 (fifteen) days, block and slides for 5 (five) years only from the time of receipt at the laboratory. No request, for any of the above, will be entertained after the due date.

Reference

- i) Rosai and Ackerman's Surgical Pathology.
- ii) Modern Surgical Pathology.


Gulshan Yadav, MD
Consultant Pathologist