

**Patient Name** Mrs. HEMLATA  
**Age/Sex** 35YRS/F  
**Patient ID** 011912200026  
**Specimen ID** MOLQ/B-2405/19

**Client Name** Chirag Diagnostics

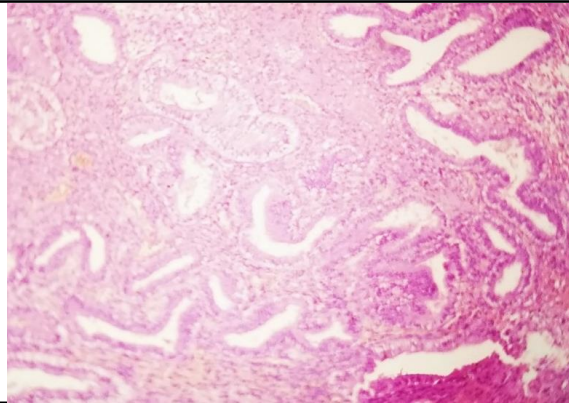
**Specimen Received** 20/12/19  
**Specimen Type** Tissue  
**Collection Date** 20/12/19  
**Report Date** 24/12/19

## SURGICAL PATHOLOGY REPORT

### Endometrium

#### DIAGNOSIS

#### DISORDERED PROLIFERATIVE PHASE



#### SPECIMEN

Endometrium

#### GROSS

Received multiple grayish white tissue piece.

#### Microscopy


Section examined shows small and tortuous endometrial glands with cuboidal lining with small round nucleus. Stroma shows mononuclear inflammatory cells.

No granuloma seen. No malignant cells seen.

**Note :** All biopsy specimen will be stored for 15 (fifteen) days, block and slides for 5 (five) years only from the time of receipt at the laboratory. No request, for any of the above, will be entertained after the due date.

#### Reference

- i) Rosai and Ackerman's Surgical Pathology.
- ii) Modern Surgical Pathology.

  
**Gulshan Yadav, MD**  
Consultant Pathologist