

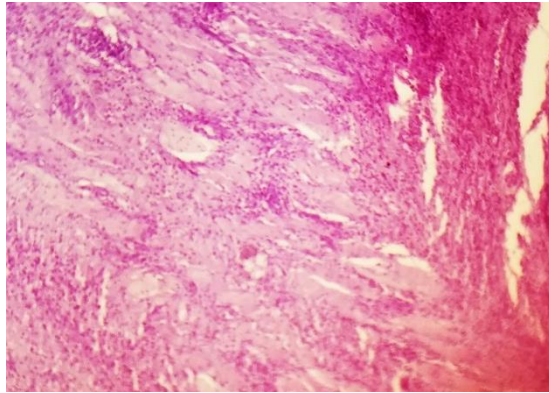
<b>Patient Name</b>	Master. HIMANSHU	<b>Client Name</b>	Brijanand Path Lab	<b>Specimen Received</b>	19/12/19
<b>Age/Sex</b>	09YRS/M			<b>Specimen Type</b>	Tissue
<b>Patient ID</b>	011912190273			<b>Collection Date</b>	19/12/19
<b>Specimen ID</b>	MOLQ/B-2404/19			<b>Report Date</b>	24/12/19

## SURGICAL PATHOLOGY REPORT

### Soft tissue lump Left hand

#### DIAGNOSIS

**INFLAMMATORY LESION**  
**(PARASITIC INFESTATION TO RULE OUT)**



#### **SPECIMEN**

Soft tissue lump Left hand

#### **GROSS**

Received 2x1cm grayish white tissue piece.

#### **Microscopy**

Section examined shows fibrocollagenous tissue with large numbers of eosinophil, Histiocytes and Lymphocytes, few areas of necrosis, muscle bundle.

No granuloma seen. No malignant cells seen.

**Note :** All biopsy specimen will be stored for 15 (fifteen) days, block and slides for 5 (five) years only from the time of receipt at the laboratory. No request, for any of the above, will be entertained after the due date.

#### **Reference**

- i) Rosai and Ackerman's Surgical Pathology.
- ii) Modern Surgical Pathology.

**Gulshan Yadav, MD**  
**Consultant Pathologist**