

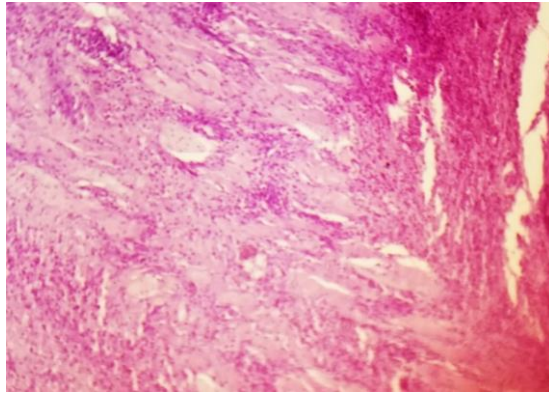
Patient Name	Master. HIMANSHU	Client Name	Brijanand Path Lab	Specimen Received	19/12/19
Age/Sex	09YRS/M			Specimen Type	Tissue
Patient ID	011912190273			Collection Date	19/12/19
Specimen ID	MOLQ/B-2404/19			Report Date	24/12/19

SURGICAL PATHOLOGY REPORT

Soft tissue lump Left hand

DIAGNOSIS

INFLAMMATORY LESION
(PARASITIC INFACTIONS TO RULE OUT)



SPECIMEN

Soft tissue lump Left hand

GROSS

Received 2x1cm grayish white tissue piece.

Microscopy

Section examined shows fibrocollagenous tissue with large numbers of eosinophil ,Histiocytes and Lymphocytes, few areas of necrosis ,muscle bundle .

No granuloma seen. No malignant cells seen.

Note : All biopsy specimen will be stored for 15 (fifteen)days, block and slides for 5(five) years only from the time of receipt at the laboratory. No request ,for any of the above ,will be entertained after the due date.

Reference

- i) Rosai and Ackerman's Surgical Pathology.
- ii) Modern Surgical Pathology.

Gulshan Yadav, MD
Consultant Pathologist