

Patient Name Mrs. ASHA
Age/Sex 26YRS/F
Patient ID 011912180301
Specimen ID MOLQ/B-2393/19

Client Name Lalita Memorial Hospital Pvt.
Ltd. (Rewari)

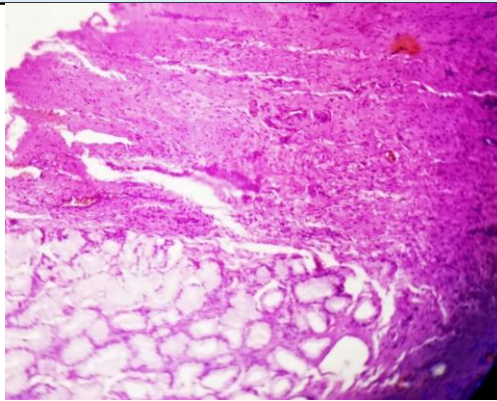
Specimen Received 18/12/19
Specimen Type Tissue
Collection Date 18/12/19
Report Date 24/12/19

SURGICAL PATHOLOGY REPORT

Bartholin cyst

DIAGNOSIS

BENIGN CYSTIC LESION



SPECIMEN

Bartholin cyst

GROSS

Received 1x1cm grayish white cystic tissue piece.

Microscopy


Section examined shows squamous lining epithelial cells with glands having columnar round to oval nucleus, fibrocollagenous tissue and blood vessels.

No granuloma seen. No malignant cells seen.

Note : All biopsy specimen will be stored for 15 (fifteen) days, block and slides for 5 (five) years only from the time of receipt at the laboratory. No request, for any of the above, will be entertained after the due date.

Reference

- i) Rosai and Ackerman's Surgical Pathology.
- ii) Modern Surgical Pathology.


Gulshan Yadav, MD
Consultant Pathologist