

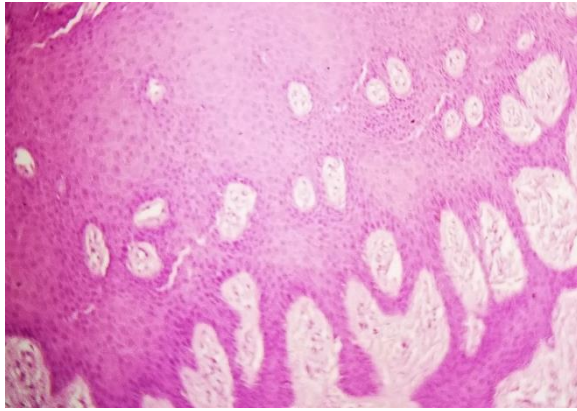
Patient Name	Mrs. BIRMA DEVO	Client Name	Pushpanjali Hospital (Rewari)	Specimen Received	16/12/19
Age/Sex	75YRS/F			Specimen Type	Tissue
Patient ID	011912160230			Collection Date	16/12/19
Specimen ID	MOLQ/B-2366/19			Report Date	23/12/19

SURGICAL PATHOLOGY REPORT

Swelling Lateral Malleolus (? Bursitis)

DIAGNOSIS

HYPERKERATOTIC LESION WITH SQUAMOUS HYPERPLASIA



SPECIMEN

Swelling Lateral Malleolus (? Bursitis)

GROSS

Received multiple greyish white tissue piece, measuring 3x2 cm.

Microscopy

Section examined shows squamous lining epithelium with mild hyperplasia with round to oval nucleus with hyperkeratosis. Deeper tissue shows fibrocollagenous tissue, blood vessels with mild inflammation.

No granuloma and no malignant cells seen.

Note : All biopsy specimen will be stored for 15 (fifteen)days, block and slides for 5(five) years only from the time of receipt at the laboratory. No request ,for any of the above ,will be entertained after the due date.

Reference

- i) Rosai and Ackerman's Surgical Pathology.
- ii) Modern Surgical Pathology.

Gulshan Yadav, MD
Consultant Pathologist