

Patient Name Ms. SUSHMA
Age/Sex 27YRS/F
Patient ID 011912180299
Specimen ID MOLQ/B-2392/19

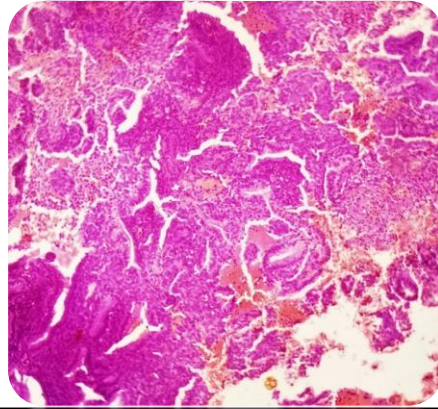
Client Name Pushpanjali Hospital (Rewari) **Specimen Received** 18/12/19
Specimen Type Tissue
Collection Date 18/12/19
Report Date 21/12/19

SURGICAL PATHOLOGY REPORT

Endometrium

DIAGNOSIS

DISORDERED PROLIFERATIVE PHASE.



SPECIMEN

Endometrium

GROSS

Received multiple grayish white tissue piece.

Microscopy


Section examined shows small and tortuous endometrial glands with cuboidal lining with small round nucleus. Stroma shows mononuclear inflammatory cells.

No granuloma seen. No malignant cells seen.

Note : All biopsy specimen will be stored for 15 (fifteen) days, block and slides for 5 (five) years only from the time of receipt at the laboratory. No request, for any of the above, will be entertained after the due date.

Reference

- i) Rosai and Ackerman's Surgical Pathology.
- ii) Modern Surgical Pathology.


Gulshan Yadav, MD
Consultant Pathologist