

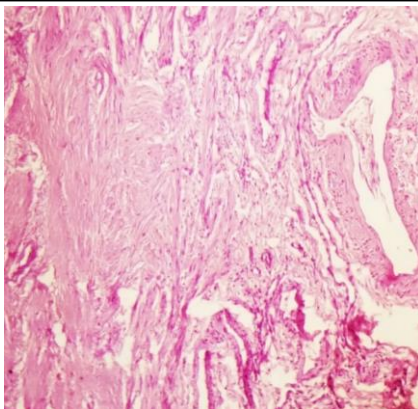
<b>Patient Name</b>	Ms. ANITA DEVI	<b>Client Name</b>	Pushpanjali Hospital (Rewari)	<b>Specimen Received</b>	18/12/19
<b>Age/Sex</b>	27YRS/F			<b>Specimen Type</b>	Tissue
<b>Patient ID</b>	011912180298			<b>Collection Date</b>	18/12/19
<b>Specimen ID</b>	MOLQ/B-2391/19			<b>Report Date</b>	21/12/19

## SURGICAL PATHOLOGY REPORT

### Gall Bladder

#### DIAGNOSIS

**CHOLECYSTITIS .**



#### SPECIMEN

Gall Bladder

#### GROSS

Received 7x2.2cm long gall bladder. Already Cut Open no stones. wall thickness 0.3mm

#### Microscopy

Section examined shows ulcerative mucosa and Rokitansky Aschoff sinus (irregularly shaped tubular structures lined by cuboidal lining epithelium with round to oval nucleus) with fibro collagenous tissue and inflammatory cells (lymphocytes).

**Note :** All biopsy specimen will be stored for 15 (fifteen)days, block and slides for 5(five) years only from the time of receipt at the laboratory. No request ,for any of the above ,will be entertained after the due date.

#### Reference

- i) Rosai and Ackerman's Surgical Pathology.
- ii) Modern Surgical Pathology.

**Gulshan Yadav, MD**  
Consultant Pathologist