

Patient Name Mr. DHIRAJ
Age/Sex 71YRS/M
Patient ID 011912180256
Specimen ID MOLQ/B-2388/19

Client Name Kriti Hospital

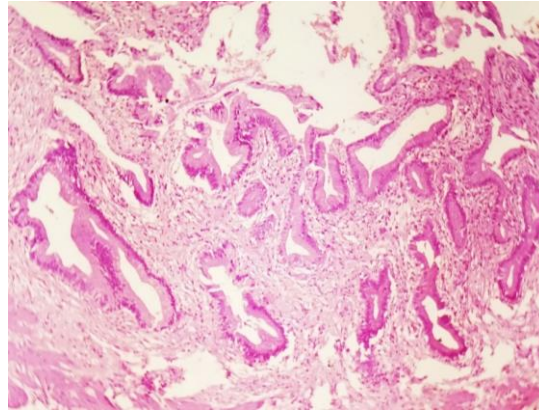
Specimen Received 18/12/19
Specimen Type Tissue
Collection Date 18/12/19
Report Date 21/12/19

SURGICAL PATHOLOGY REPORT

Gall Bladder

DIAGNOSIS

CHOLECYSTITIS AND CHOLELITHIASIS.



SPECIMEN

Gall Bladder

GROSS

Received 6x2.4cm long gall bladder. already Cut Open with tiny stones. wall thickness 0.3 mm.


Microscopy

Section examined shows ulcerative mucosa and Rokitansky-Aschoff sinuses (irregularly shaped tubular structures lined by cuboidal lining epithelium with round to oval nucleus) with fibro collagenous tissue and inflammatory cells (lymphocytes).

Note : All biopsy specimen will be stored for 15 (fifteen) days, block and slides for 5 (five) years only from the time of receipt at the laboratory. No request, for any of the above, will be entertained after the due date.

Reference

- i) Rosai and Ackerman's Surgical Pathology.
- ii) Modern Surgical Pathology.


Gulshan Yadav, MD
Consultant Pathologist