

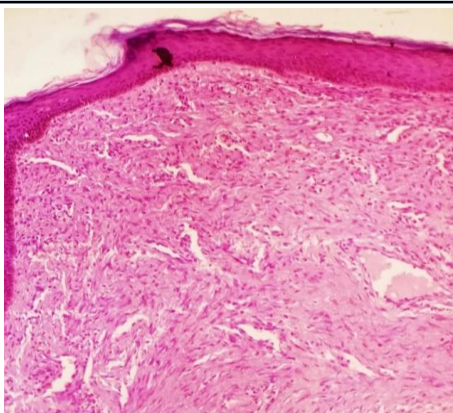
Patient Name	Ms. SEEMA SEHGAL	Client Name	Polaris Hospital	Specimen Received	18/12/19
Age/Sex	46YRS/F			Specimen Type	Tissue
Patient ID	011912180137			Collection Date	18/12/19
Specimen ID	MOLQ/B-2384/19			Report Date	21/12/19

SURGICAL PATHOLOGY REPORT

Infected Sebaceous Cyst

DIAGNOSIS

Sebaceous Cyst



SPECIMEN

Infected Sebaceous Cyst

GROSS

Received Two grayish white tissue piece, 2x2 cm in aggregate.

Microscopy

Section examined shows squamous lining epithelium cells with keratin and deeper tissue shows fibro collagenous tissue , blood vessels and hairs.

No granuloma seen. No malignant cells seen.

Note : All biopsy specimen will be stored for 15 (fifteen)days, block and slides for 5(five) years only from the time of receipt at the laboratory. No request ,for any of the above ,will be entertained after the due date.

Reference

- i) Rosai and Ackerman's Surgical Pathology.
- ii) Modern Surgical Pathology.

Gulshan Yadav, MD
Consultant Pathologist