

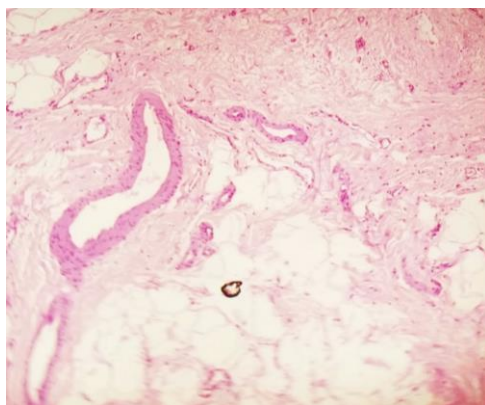
Patient Name	Mr. RANJEET SINGH	Client Name	S. M. Diagnostics, Kaithal	Specimen Received	18/12/19
Age/Sex	69YRS/M			Specimen Type	Tissue
Patient ID	011912180097			Collection Date	18/12/19
Specimen ID	MOLQ/B-2377/19			Report Date	21/12/19

SURGICAL PATHOLOGY REPORT

Gall Bladder

DIAGNOSIS

CHOLECYSTITIS AND CHOLELITHIASIS.



SPECIMEN

Gall Bladder

GROSS

Received autolyzed 5.2x2.8cm long gall bladder. Already Cut Open with stones. wall thickness 0.3 mm.


Microscopy

Section examined shows ulcerative mucosa and Rokitansky-Aschoff sinus (irregularly shaped tubular structures lined by cuboidal lining epithelium with round to oval nucleus) with fibrocollagenous tissue and inflammatory cells (lymphocytes).

Note : All biopsy specimen will be stored for 15 (fifteen) days, block and slides for 5 (five) years only from the time of receipt at the laboratory. No request, for any of the above, will be entertained after the due date.

Reference

- i) Rosai and Ackerman's Surgical Pathology.
- ii) Modern Surgical Pathology.


Gulshan Yadav, MD
Consultant Pathologist