

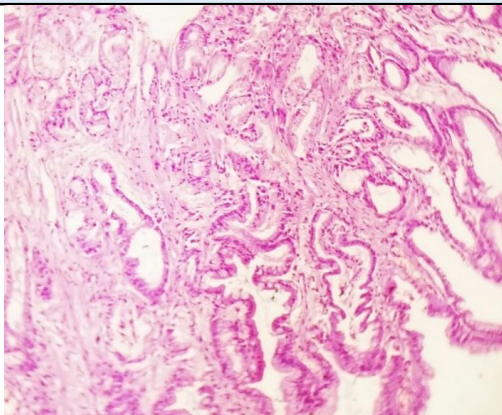
Patient Name	Mrs. BEENO DEVI	Client Name	S. M. Diagnostics, Kaithal	Specimen Received	18/12/19
Age/Sex	55YRS/F			Specimen Type	Tissue
Patient ID	011912180096			Collection Date	18/12/19
Specimen ID	MOLQ/B-2376/19			Report Date	21/12/19

SURGICAL PATHOLOGY REPORT
Endoscopic Biopsy (Growth Pylorus)

DIAGNOSIS

DYSPLASTIC LESION

(SUGGESTIVE OF MODERATELY DIFFERENTIATED ADENOCARCINOMA)



SPECIMEN

Endoscopic Biopsy (Growth Pylorus)

GROSS

Received tiny grayish white tissue piece.


Microscopy

Section examined shows mucosal lining epithelium with columnar cells and submucosal glands with surrounding tissue. Section also shows areas of atypical glands with anisonucleosis along with atypical irregular nucleus.

Note : All biopsy specimen will be stored for 15 (fifteen)days, block and slides for 5(five) years only from the time of receipt at the laboratory. No request ,for any of the above ,will be entertained after the due date.

Reference

- i) Rosai and Ackerman's Surgical Pathology.
- ii) Modern Surgical Pathology.


Gulshan Yadav, MD
Consultant Pathologist