

Patient Name Mr. JAIPAL
Age/Sex 46YRS/M
Patient ID 011912160296
Specimen ID MOLQ/B-2370/19

Client Name S. M. Diagnostics, Kaithal

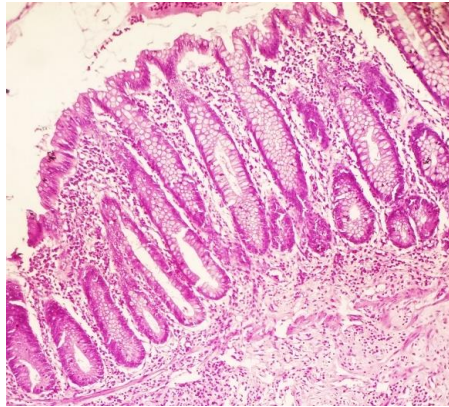
Specimen Received 16/12/19
Specimen Type Tissue
Collection Date 16/12/19
Report Date 20/12/19

SURGICAL PATHOLOGY REPORT

Appendix

DIAGNOSIS

ACUTE APPENDICITIS



SPECIMEN

Appendix

GROSS

Received 5.1x1.9cm long appendix. Cut section shows feco-lith.


Microscopy

Section examined shows lymphoid follicles with ulcerative mucosa. Deeper tissue shows inflammatory cells (polymorphs and lymphocytes). No granuloma seen. No malignant cells seen.

Note : All biopsy specimen will be stored for 15 (fifteen)days, block and slides for 5(five) years only from the time of receipt at the laboratory. No request ,for any of the above ,will be entertained after the due date.

Reference

- i) Rosai and Ackerman's Surgical Pathology.
- ii) Modern Surgical Pathology.


Gulshan Yadav, MD
Consultant Pathologist