

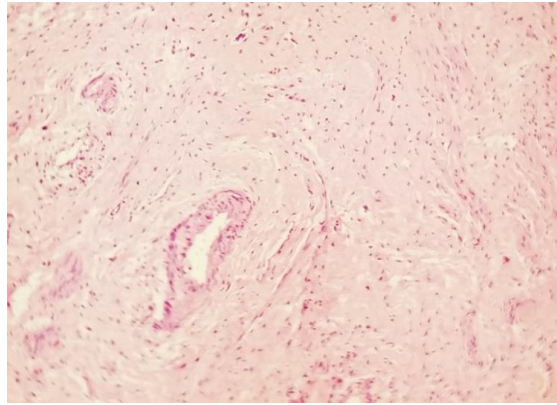
<b>Patient Name</b>	Mrs. KHETABO	<b>Client Name</b>	Pushpanjali Hospital (Rewari)	<b>Specimen Received</b>	16/12/19
<b>Age/Sex</b>	63YRS/F			<b>Specimen Type</b>	Tissue
<b>Patient ID</b>	011912160228			<b>Collection Date</b>	16/12/19
<b>Specimen ID</b>	MOLQ/B-2364/19			<b>Report Date</b>	20/12/19

## SURGICAL PATHOLOGY REPORT

### Uterus with Cervix

#### DIAGNOSIS

#### CHRONIC CERVICITIS



#### SPECIMEN

Uterus with Cervix

#### GROSS

Received 6.5x4 cm uterus with cervix with bilateral adnexa. Ovary size 2x2 cm, 2x2 cm.

#### Microscopy


Section examined shows

- 1) Endometrium with proliferative phase
- 2) Myometrium with muscle bundles
- 3) Cervix with mononuclear inflammatory cells
- 4) Ovary with Luteal cyst and tube unremarkable
- 5) Other ovary Luteal cyst and tube unremarkable

**Note** : All biopsy specimen will be stored for 15 (fifteen) days, block and slides for 5 (five) years only from the time of receipt at the laboratory. No request, for any of the above, will be entertained after the due date.

#### Reference

- i) Rosai and Ackerman's Surgical Pathology.
- ii) Modern Surgical Pathology.

  
**Gulshan Yadav, MD**  
**Consultant Pathologist**