

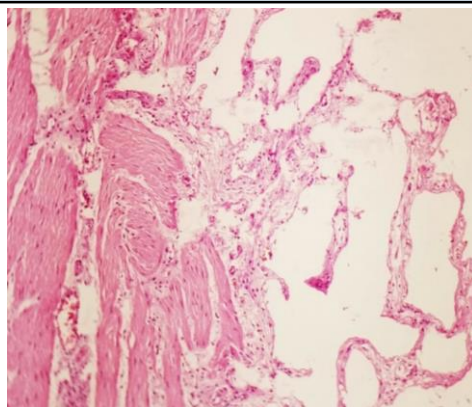
| | | | | | |
|---------------------|----------------|--------------------|--|--------------------------|----------|
| Patient Name | Mrs. REETA | Client Name | Shri Balaji Multispeciality Hospital-Gurgaon | Specimen Received | 16/12/19 |
| Age/Sex | 38YRS/F | | | Specimen Type | Tissue |
| Patient ID | 011912160148 | | | Collection Date | 16/12/19 |
| Specimen ID | MOLQ/B-2363/19 | | | Report Date | 20/12/19 |

SURGICAL PATHOLOGY REPORT

Gall Bladder

DIAGNOSIS

CHOLECYSTITIS AND CHOLELITHIASIS.



SPECIMEN

Gall Bladder

GROSS

Received Autolyzed 9x2.5cm long gall bladder. already Cut Open with multiple stones.

Microscopy

Section examined shows ulcerative mucosa and Rokitansky-Aschoff sinuses (irregularly shaped tubular structures lined by cuboidal lining epithelium with round to oval nucleus) with fibrocollagenous tissue and inflammatory cells (lymphocytes).

Note : All biopsy specimen will be stored for 15 (fifteen) days, block and slides for 5 (five) years only from the time of receipt at the laboratory. No request, for any of the above, will be entertained after the due date.

Reference

- i) Rosai and Ackerman's Surgical Pathology.
- ii) Modern Surgical Pathology.

Gulshan Yadav, MD
Consultant Pathologist