

Patient Name Mrs. MEENU
Age/Sex 50YRS/F
Patient ID 011912140220
Specimen ID MOLQ/B-2352/19

Client Name Pushpanjali Hospital
(Rewari)

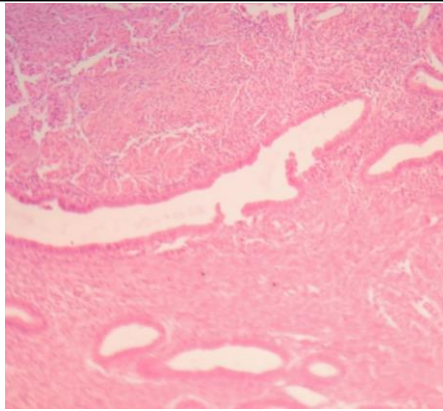
Specimen Received 14/12/19
Specimen Type Tissue
Collection Date 14/12/19
Report Date 18/12/19

SURGICAL PATHOLOGY REPORT

Uterus with Cervix

DIAGNOSIS

CHRONIC CERVICITIS WITH ENDOMETRIAL POLYP



SPECIMEN

Uterus with Cervix

GROSS

Received 10.2x9.5 cm uterus with cervix with unilateral tube already cut open with 1x1cm polyp.

Microscopy


Section examined shows

- 1) Endometrium with proliferative phase
- 2) Myometrium with adenomyosis
- 3) Cervix with mononuclear inflammatory cells
- 4) Tube is unremarkable
- 5) Polyp with Endometrial polyp having cuboidal to columnar lining epithelium with round to oval nucleus.

Note : All biopsy specimen will be stored for 15 (fifteen) days, block and slides for 5 (five) years only from the time of receipt at the laboratory. No request, for any of the above, will be entertained after the due date.

Reference

- i) Rosai and Ackerman's Surgical Pathology.
- ii) Modern Surgical Pathology.


Gulshan Yadav, MD
Consultant Pathologist