

Patient Name Mr. RAMJAN
Age/Sex 21YRS/M
Patient ID 011912140067
Specimen ID MOLQ/B-2349/19

Client Name Kriti Hospital

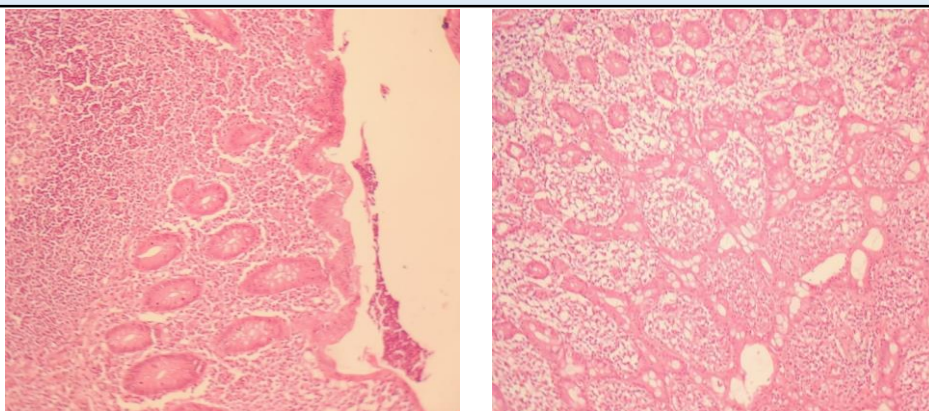
Specimen Received 14/12/19
Specimen Type Tissue
Collection Date 14/12/19
Report Date 18/12/19

SURGICAL PATHOLOGY REPORT

Appendix (Perforated Ileal Diverticulum)

DIAGNOSIS

ACUTE APPENDICITIS WITH DIVERTICULUM



SPECIMEN

Appendix (Perforated Ileal Diverticulum)

GROSS

Container 1: (A) Received 5x2 cm long appendix. Cut section shows feco-lith.
Container 2: (B) Received 3x2 cm greyish white tissue piece.


Microscopy

(A) Section examined shows lymphoid follicles with ulcerative mucosa. Deeper tissue shows inflammatory cells (polymorphs and lymphocytes). No granuloma seen. No malignant cells seen.
(B) Section examined shows submucosal glands with mucosal lining epithelium and lymphoid follicles. No granuloma seen. No malignant cells seen.

Note : All biopsy specimen will be stored for 15 (fifteen)days, block and slides for 5(five) years only from the time of receipt at the laboratory. No request ,for any of the above ,will be entertained after the due date.

Reference

- Rosai and Ackerman's Surgical Pathology.
- Modern Surgical Pathology.


Gulshan Yadav, MD
Consultant Pathologist