

Patient Name Mrs. SEEMA
Age/Sex 22YRS/F
Patient ID 011912120055
Specimen ID MOLQ/B-2334/19

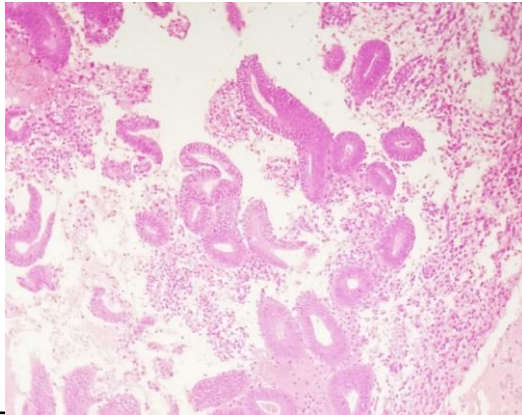
Client Name Chirag Diagnostics

Specimen Received 12/12/19
Specimen Type Tissue
Collection Date 12/12/19
Report Date 16/12/19

SURGICAL PATHOLOGY REPORT
Endometrium

DIAGNOSIS

DISORDERED PROLIFERATIVE PHASE



SPECIMEN

Endometrium

GROSS

Received multiple grayish white tissue piece.

Microscopy


Section examined shows small and tortuous endometrial glands with columnar lining with small round to oval nucleus. Stroma shows mononuclear inflammatory cells and RBCs.

No granuloma seen. No malignant cells seen.

Note : All biopsy specimen will be stored for 15 (fifteen) days, block and slides for 5 (five) years only from the time of receipt at the laboratory. No request, for any of the above, will be entertained after the due date.

Reference

- i) Rosai and Ackerman's Surgical Pathology.
- ii) Modern Surgical Pathology.


Gulshan Yadav, MD
Consultant Pathologist