

Patient Name Ms. NANDINI
Age/Sex 30YRS/F
Patient ID 011912110177
Specimen ID MOLQ/B-2324/19

Client Name Path Star Diagnostic

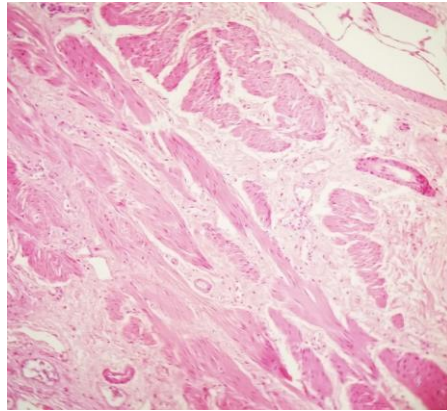
Specimen Received 11/12/19
Specimen Type Tissue
Collection Date 11/12/19
Report Date 14/12/19

SURGICAL PATHOLOGY REPORT

Gall Bladder

DIAGNOSIS

CHOLECYSTITIS AND CHOLELITHIASIS.



SPECIMEN

Gall Bladder

GROSS

Received 6.4x2.9cm long gall bladder. Cut section shows stones. wall thickness 0.3 mm.


Microscopy

1. Section examined shows ulcerative mucosa and rokitansky aschoff sinus (irregularly shaped tubular structures lined by cuboidal lining epithelium with round to oval nucleus) with fibro collagenous tissue and inflammatory cells (lymphocytes).

Note : All biopsy specimen will be stored for 15 (fifteen)days, block and slides for 5(five) years only from the time of receipt at the laboratory. No request ,for any of the above ,will be entertained after the due date.

Reference

- i) Rosai and Ackerman's Surgical Pathology.
- ii) Modern Surgical Pathology.


Gulshan Yadav, MD
Consultant Pathologist