

Patient Name Ms. GUDDO DEVI
Age/Sex 46YRS/F
Patient ID 011912100041
Specimen ID MOLQ/B-2322/19

Client Name Kamal Hospital and Maternity
Centre

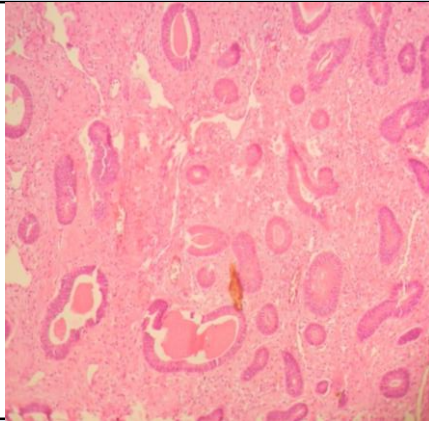
Specimen Received 10/12/19
Specimen Type Tissue
Collection Date 10/12/19
Report Date 13/12/19

SURGICAL PATHOLOGY REPORT

Uterus with Cervix

DIAGNOSIS

CHRONIC CERVICITIS WITH ENDOMETRIAL POLYP



SPECIMEN

Uterus with Cervix

GROSS

Received 10.8x4.9 cm uterus with cervix. Cut section shows 2x1 cm polyp.

Microscopy


Section examined shows

- 1) Endometrium with proliferative phase
- 2) Myometrium with muscle bundles
- 3) Cervix with mononuclear inflammatory cells
- 4) Poly with endometrial glands having cuboidal lining epithelium with small round nucleus suggestive of Endometrial Polyp.

Note : All biopsy specimen will be stored for 15 (fifteen) days, block and slides for 5 (five) years only from the time of receipt at the laboratory. No request, for any of the above, will be entertained after the due date.

Reference

- i) Rosai and Ackerman's Surgical Pathology.
- ii) Modern Surgical Pathology.


Gulshan Yadav, MD
Consultant Pathologist