

Patient Name Ms. GEETA
Age/Sex 40YRS/F
Patient ID 011912100030
Specimen ID MOLQ/B-2320/19 (B)

Client Name Pushpanjali Hospital
(Rewari)

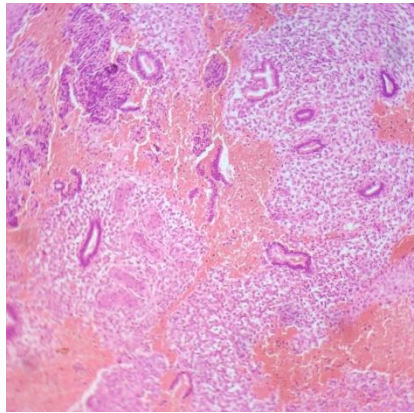
Specimen Received 10/12/19
Specimen Type Tissue
Collection Date 10/12/19
Report Date 13/12/19

SURGICAL PATHOLOGY REPORT

Endometrium

DIAGNOSIS

PROLIFERATIVE PHASE



SPECIMEN

Endometrium

GROSS

Received multiple grayish white tissue piece.


Microscopy

1. Section examined shows small endometrial glands with cuboidal lining with small round nucleus.
2. Stroma shows mononuclear inflammatory cells.
3. No granuloma seen.
4. No malignant cells seen.

Note : All biopsy specimen will be stored for 15 (fifteen) days, block and slides for 5 (five) years only from the time of receipt at the laboratory. No request, for any of the above, will be entertained after the due date.

Reference

- i) Rosai and Ackerman's Surgical Pathology.
- ii) Modern Surgical Pathology.


Gulshan Yadav, MD
Consultant Pathologist