

Patient Name Ms. GEETA
Age/Sex 40YRS/F
Patient ID 011912100030
Specimen ID MOLQ/B-2320/19 (A)

Client Name Pushpanjali Hospital
(Rewari)

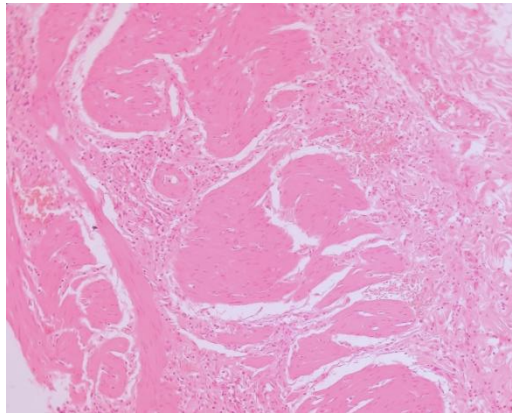
Specimen Received 10/12/19
Specimen Type Tissue
Collection Date 10/12/19
Report Date 13/12/19

SURGICAL PATHOLOGY REPORT

Gall Bladder

DIAGNOSIS

CHOLECYSTITIS AND CHOLELITHIASIS.



SPECIMEN

Gall Bladder

GROSS

Received 6.6x2.9 cm long gall bladder. Cut section shows stones. Wall Thickness 0.4 mm.


Microscopy

1. Section examined shows ulcerative mucosa and Rokitansky-Aschoff sinuses (irregularly shaped tubular structures lined by cuboidal lining epithelium with round to oval nucleus) with fibro collagenous tissue and inflammatory cells (lymphocytes).

Note : All biopsy specimen will be stored for 15 (fifteen) days, block and slides for 5 (five) years only from the time of receipt at the laboratory. No request, for any of the above, will be entertained after the due date.

Reference

- i) Rosai and Ackerman's Surgical Pathology.
- ii) Modern Surgical Pathology.


Gulshan Yadav, MD
Consultant Pathologist