

Patient Name Mrs. SAVITA
Age/Sex 51YRS/F
Patient ID 011912070216
Specimen ID MOLQ/B-2306/19

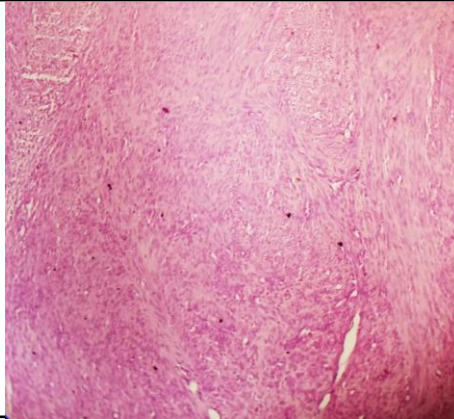
Client Name Pushpanjali Hospital (Rewari)
Specimen Received 07/12/19
Specimen Type Tissue
Collection Date 07/12/19
Report Date 13/12/19

SURGICAL PATHOLOGY REPORT

Uterus with Cervix

DIAGNOSIS

LEIOMYOMA



SPECIMEN

Uterus with Cervix

GROSS

Received 11.1x9.6 cm uterus with cervix with Bilateral tubes, cut section shows 1.4x1.3cm fibroid.

Microscopy


Section examined shows

- 1)Endometrium with proliferative phase
- 2)Myometrium with muscle bundles
- 3)Cervix with mononuclear inflammatory cells
- 4)Fibroid with interlacing muscle bundle
- 5)Bilateral tubes unremarkable

Note : All biopsy specimen will be stored for 15 (fifteen)days, block and slides for 5(five) years only from the time of receipt at the laboratory. No request ,for any of the above ,will be entertained after the due date.

Reference

- i) Rosai and Ackerman's Surgical Pathology.
- ii) Modern Surgical Pathology.


Gulshan Yadav, MD
Consultant Pathologist