

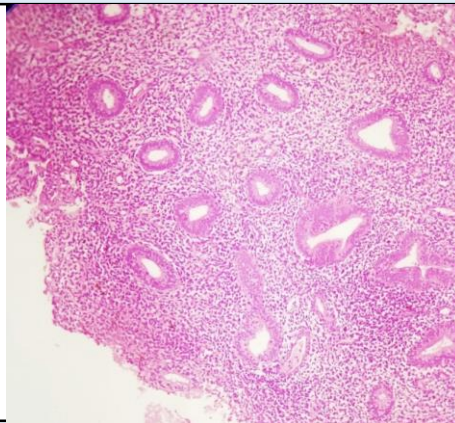
Patient Name	Mrs. MANJU RANA	Client Name	Path Star Diagnostic	Specimen Received	09/12/19
Age/Sex	39YRS/F			Specimen Type	Tissue
Patient ID	011912090139			Collection Date	09/12/19
Specimen ID	MOLQ/B-2316/19			Report Date	12/12/19

SURGICAL PATHOLOGY REPORT

Endometrium

DIAGNOSIS

PROLIFERATIVE PHASE



SPECIMEN

Endometrium

GROSS

Received multiple grayish white tissue piece.


Microscopy

1. Section examined shows small endometrial glands with columnar lining epithelial with small round to oval nucleus.
2. Stroma shows mononuclear inflammatory cells.
3. No granuloma seen. No malignant cells seen.

Note : All biopsy specimen will be stored for 15 (fifteen) days, block and slides for 5 (five) years only from the time of receipt at the laboratory. No request, for any of the above, will be entertained after the due date.

Reference

- i) Rosai and Ackerman's Surgical Pathology.
- ii) Modern Surgical Pathology.


Gulshan Yadav, MD
Consultant Pathologist