

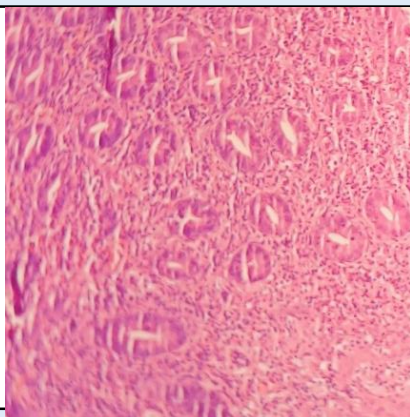
Patient Name	Mr. MANJEET	Client Name	Shri Balaji Multispeciality Hospital-Gurgaon	Specimen Received	08/12/19
Age/Sex	15YRS/M			Specimen Type	Tissue
Patient ID	011912080118			Collection Date	08/12/19
Specimen ID	MOLQ/B-2310/19			Report Date	12/12/19

SURGICAL PATHOLOGY REPORT

Appendix

DIAGNOSIS

ACUTE APPENDICITIS



SPECIMEN

Appendix

GROSS

Received 4.6x1.6 cm long appendix. Cut section shows fecolith.

Microscopy

1. Section examined shows lymphoid follicles with ulcerative mucosa.
2. Deeper tissue shows inflammatory cells (polymorphs and lymphocytes).
3. No granuloma seen.
4. No malignant cells seen.

Note : All biopsy specimen will be stored for 15 (fifteen)days, block and slides for 5(five) years only from the time of receipt at the laboratory. No request ,for any of the above ,will be entertained after the due date.

Reference

- i) Rosai and Ackerman's Surgical Pathology.
- ii) Modern Surgical Pathology.

Gulshan Yadav, MD
Consultant Pathologist