

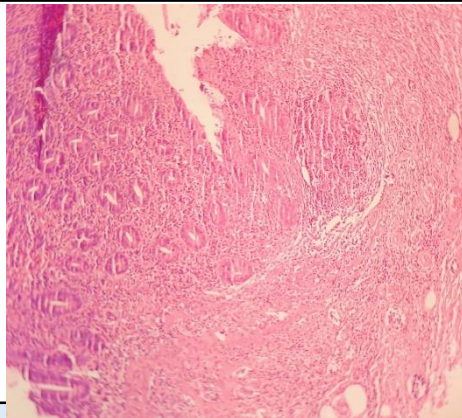
Patient Name	Mrs. PRATIMA	Client Name	Umkal Hospital	Specimen Received	07/12/19
Age/Sex	30YRS/F			Specimen Type	Tissue
Patient ID	011912070214			Collection Date	07/12/19
Specimen ID	MOLQ/B-2305/19			Report Date	12/12/19

SURGICAL PATHOLOGY REPORT

Appendix

DIAGNOSIS

ACUTE APPENDICITIS



SPECIMEN

Appendix

GROSS

Received two greyish white tissue piece measuring 2.3x1.2 and 1x1 cm.

Microscopy

Section examined shows lymphoid follicles with ulcerative mucosa. Deeper tissue shows inflammatory cells (polymorphs and lymphocytes). No granuloma seen. No malignant cells seen.

Note : All biopsy specimen will be stored for 15 (fifteen)days, block and slides for 5(five) years only from the time of receipt at the laboratory. No request ,for any of the above ,will be entertained after the due date.

Reference

- i) Rosai and Ackerman's Surgical Pathology.
- ii) Modern Surgical Pathology.

Gulshan Yadav, MD
Consultant Pathologist