

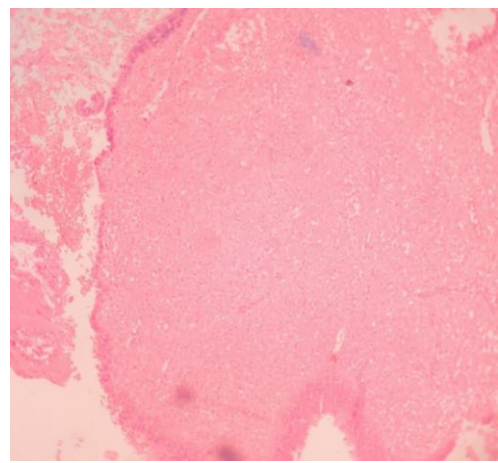
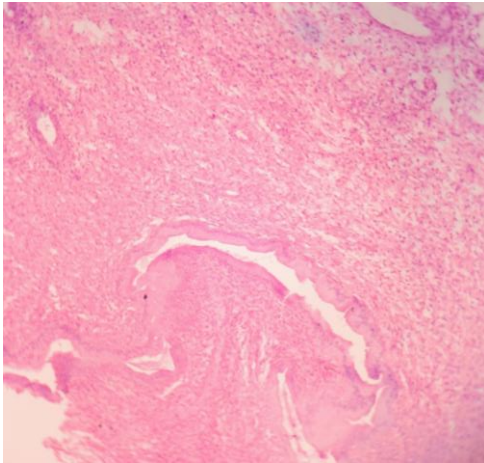
Patient Name	Mrs. NIRMALA	Client Name	Path Star Diagnostic	Specimen Received	06-Nov-2019
Age/Sex	50 Years/Female			Specimen Type	Tissue
Patient ID	011912060172			Collection Date	06-Nov-2019
Specimen ID	MOLQ/B-2300/19			Report Date	11-Nov-2019

SURGICAL PATHOLOGY REPORT

Container 1 (A): Cervical Polyp Container 2 (B): Endometrium Biopsy

DIAGNOSIS

A): ENDOCERVICAL POLYP
B) : EARLY SECRETORY PHASE



SPECIMEN

Container 1 (A): Cervical Polyp
 Container 2 (B): Endometrium Biopsy

GROSS

A):Received 1x1 cm and 0.5x 1 cm grayish white tissue piece.
 B):Received multiple grayish white tissue piece.

Microscopy

A) Section examined shows Endocervical glands with columnar lining epithelium having round to oval nucleus. Section also shows squamous cells. No granuloma seen. No malignant cells seen.

B) Section examined shows small and few tortuous endometrial glands (with secretions) with cuboidal lining with small round nucleus. Stroma shows mononuclear inflammatory cells. No granuloma seen. No malignant cells seen.

Note : All biopsy specimen will be stored for 15 (fifteen)days, block and slides for 5(five) years only from the time of receipt at the laboratory. No request ,for any of the above ,will be entertained after the due date.

Reference

- i) Rosai and Ackerman's Surgical Pathology.
- ii) Modern Surgical Pathology.

Gulshan Yadav, MD
Consultant Pathologist