

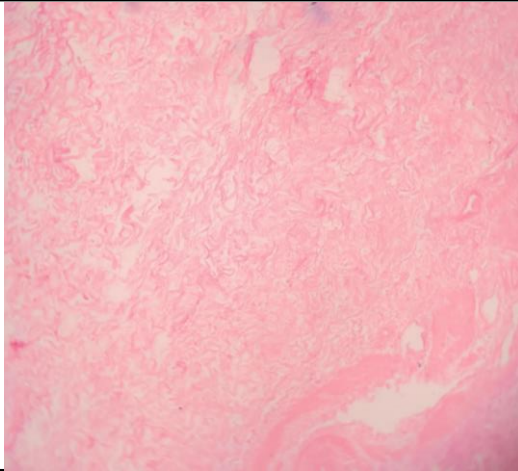
Patient Name	Mr. SANJAY	Client Name	Civil Hospital Sec-10	Specimen Received	06-Nov-2019
Age/Sex	42 Years/Male			Specimen Type	Tissue
Patient ID	011912060061			Collection Date	06-Nov-2019
Specimen ID	MOLQ/B-2298/19			Report Date	11-Nov-2019

SURGICAL PATHOLOGY REPORT

Gall Bladder

DIAGNOSIS

CHOLECYSTITIS AND CHOLELITHIASIS.



SPECIMEN

Gall Bladder

GROSS

Received 6x2.1 cm long gall bladder with thickened wall (0.8 mm).
Cut section shows stones..

Microscopy

1. Section examined shows ulcerative mucosa and rokitansky aschoff sinus (irregularly shaped tubular structures lined by cuboidal lining epithelium with round to oval nucleus) with fibro collagenous tissue and inflammatory cells (lymphocytes).

Note : All biopsy specimen will be stored for 15 (fifteen)days, block and slides for 5(five) years only from the time of receipt at the laboratory. No request ,for any of the above ,will be entertained after the due date.

Reference

- i) Rosai and Ackerman's Surgical Pathology.
- ii) Modern Surgical Pathology.

A handwritten signature in black ink, appearing to read 'Gulshan', written over a light blue rectangular background.

Gulshan Yadav, MD
Consultant Pathologist