

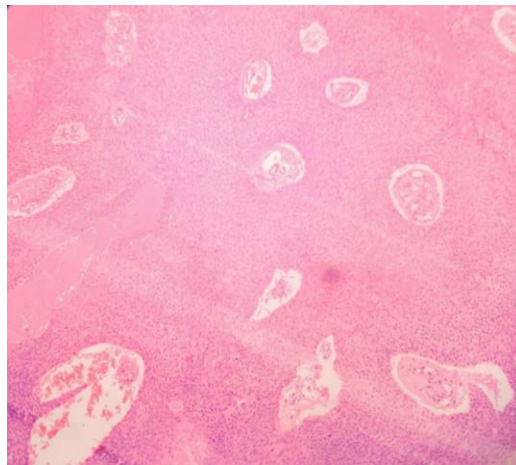
<b>Patient Name</b>	Mr. SUKHBIR	<b>Client Name</b>	Star Path Lab, NNL	<b>Specimen Received</b>	05-Nov-2019
<b>Age/Sex</b>	32 Years/Male			<b>Specimen Type</b>	Tissue
<b>Patient ID</b>	011912050193			<b>Collection Date</b>	05-Nov-2019
<b>Specimen ID</b>	MOLQ/B-2293/19			<b>Report Date</b>	11-Nov-2019

## SURGICAL PATHOLOGY REPORT

Left Shoulder Solid Mass

### DIAGNOSIS

## BENIGN ADENEXAL TUMOR



#### SPECIMEN

Left Shoulder Solid Mass

#### GROSS

Received multiple grayish white tissue piece, 2x2.1 cm in aggregate.

#### Microscopy

1. Section examined shows multilayered stromal cells with oval nucleus surrounded by blood vessels, in between fibrocollageneous tissue, nerve bundles.
2. Overlying skin shows squamous lining epithelium with round to oval nucleus (basal cells layer shows melanin pigmentation).

**Note :** All biopsy specimen will be stored for 15 (fifteen)days, block and slides for 5(five) years only from the time of receipt at the laboratory. No request ,for any of the above ,will be entertained after the due date.

#### Reference

- i) Rosai and Ackerman's Surgical Pathology.
- ii) Modern Surgical Pathology.

**Gulshan Yadav, MD**  
Consultant Pathologist