

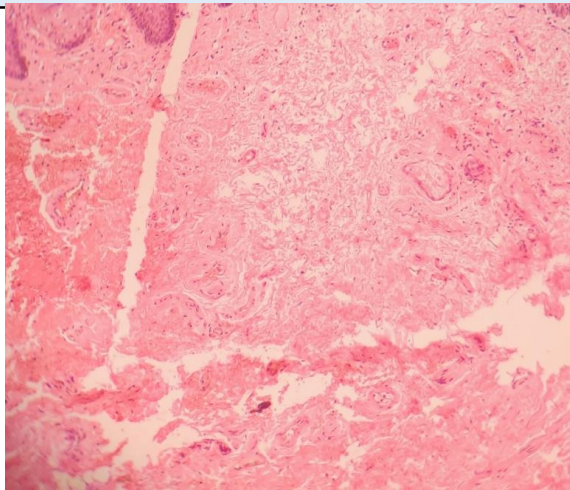
<b>Patient Name</b>	<b>Mr. M MAKBOOL</b>	<b>Client Name</b>	Faith Clinical Laboratory	<b>Specimen Received</b>	04-Dec-2019
<b>Age/Sex</b>	42 Years/Male		Jammu & Kashmir	<b>Specimen Type</b>	Tissue
<b>Patient ID</b>	011912040284			<b>Collection Date</b>	04-Dec-2019
<b>Specimen ID</b>	MOLQ/B-2289/19			<b>Report Date</b>	09-Dec-2019

## SURGICAL PATHOLOGY REPORT

Hemorrhoids

### DIAGNOSIS

### HEMORRHOIDS



#### SPECIMEN

Hemorrhoids

#### GROSS

Received multiple greyish white tissue piece, measuring 2.5x2.9 cm in aggregate.

#### Microscopy

1. Section examined shows submucosal glands, fibro collagenous tissue with blood vessels.
2. No granuloma and no malignant cells seen.

**Note :** All biopsy specimen will be stored for 15 (fifteen)days, block and slides for 5(five) years only from the time of receipt at the laboratory. No request ,for any of the above ,will be entertained after the due date.

#### Reference

- i) Rosai and Ackerman's Surgical Pathology.
- ii) Modern Surgical Pathology.

**Gulshan Yadav, MD**  
Consultant Pathologist