

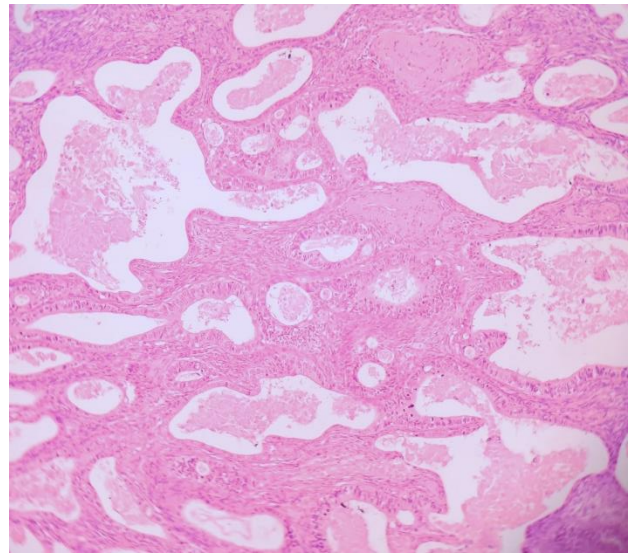
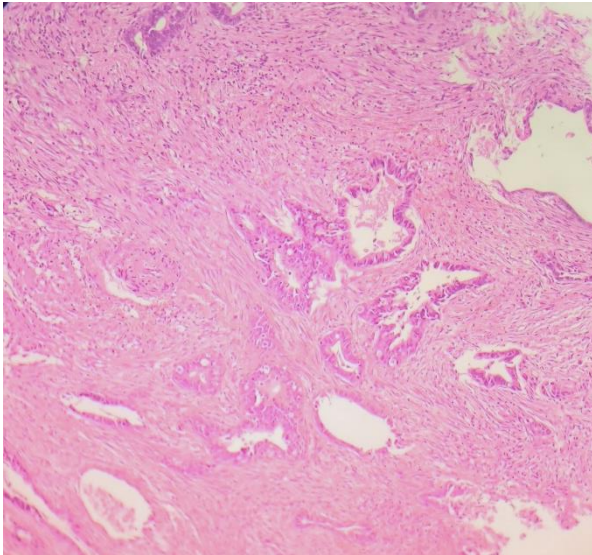
<b>Patient Name</b>	<b>Ms. MAZIDAN</b>	<b>Client Name</b>	Shiv Path Lab, Sohna	<b>Specimen Received</b>	30-Nov-2019
<b>Age/Sex</b>	55 Years/Female			<b>Specimen Type</b>	Tissue
<b>Patient ID</b>	011911300198			<b>Collection Date</b>	30-Nov-2019
<b>Specimen ID</b>	MOLQ/B-2261/19			<b>Report Date</b>	09-Dec-2019

## SURGICAL PATHOLOGY REPORT

Uterus with Cervix (Carcinoma Cervix?)

### DIAGNOSIS

**ENDOMETROID CARCINOMA [FIGO CLASSIFICATION IB]**



### SPECIMEN

Uterus with Cervix (Carcinoma Cervix?)

### GROSS

Received 6x5 cm uterus with cervix with unilateral tube.

### Reference

- i) Rosai and Ackerman's Surgical Pathology.
- ii) Modern Surgical Pathology.



**Gulshan Yadav, MD**  
Consultant Pathologist

<b>Patient Name</b>	<b>Ms. MAZIDAN</b>	<b>Client Name</b>	Shiv Path Lab, Sohna	<b>Specimen Received</b>	30-Nov-2019
<b>Age/Sex</b>	55 Years/Female			<b>Specimen Type</b>	Tissue
<b>Patient ID</b>	011911300198			<b>Collection Date</b>	30-Nov-2019
<b>Specimen ID</b>	MOLQ/B-2261/19			<b>Report Date</b>	09-Dec-2019

## Microscopy

Section examined shows

1)Endometrium and Myometrium with malignant tumor cells arranged to form variable sized glands, lined by anaplastic epithelium with enlarged, pleomorphic and hyperchromatic nuclei. Mitosis is noted. These atypical glands are seen invading the myometrium.

### Histopathological Grade

Endometroid Carcinoma

### Uterine Corpus

Not involved

### Lymph-Vascular Invasion

Absent

### Pathologic Staging (pTNM[FIGO])

pT1 [IB]: Endometroid Carcinoma confined to Uterus

### Regional Lymphnodes:

Not Sampled

### Additional Pathologic Findings

Non identified


2)Cervix with mononuclear inflammatory cells

3)Tube unremarkable

**Note :** All biopsy specimen will be stored for 15 (fifteen)days, block and slides for 5(five) years only from the time of receipt at the laboratory. No request ,for any of the above ,will be entertained after the due date.

## Reference

- i) Rosai and Ackerman's Surgical Pathology.
- ii) Modern Surgical Pathology.



**Gulshan Yadav, MD**  
**Consultant Pathologist**