

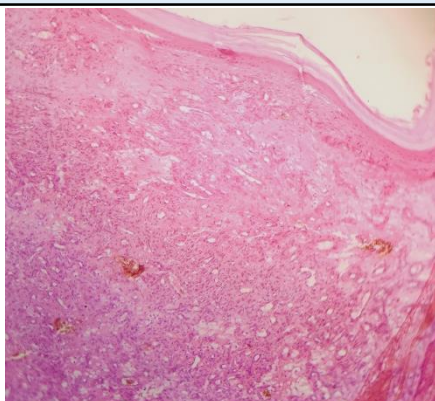
Patient Name	Mr. SURESH	Client Name	Pushpanjali Hospital (Rewari)	Specimen Received	04/12/19
Age/Sex	53YRS/M			Specimen Type	Tissue
Patient ID	011912040019			Collection Date	04/12/19
Specimen ID	MOLQ/B-2283/19			Report Date	06/12/19

SURGICAL PATHOLOGY REPORT

? Pyogenic Granuloma (Left Index Finger)

DIAGNOSIS

PYOGENIC GRANULOMA WITH HYPERKERATOTIC LESION.



SPECIMEN

? Pyogenic Granuloma (Left Index Finger)

GROSS

Received 1x1 cm grayish white tissue piece.


Microscopy

1. Section examined shows squamous lining epithelium having round to oval nucleus with hyperkeratosis and parakeratosis.
2. Deeper tissue shows large number of blood vessels.
3. No granuloma seen. No malignant cells seen.

Note : All biopsy specimen will be stored for 15 (fifteen)days, block and slides for 5(five) years only from the time of receipt at the laboratory. No request ,for any of the above ,will be entertained after the due date.

Reference

- i) Rosai and Ackerman's Surgical Pathology.
- ii) Modern Surgical Pathology.


Gulshan Yadav, MD
Consultant Pathologist