

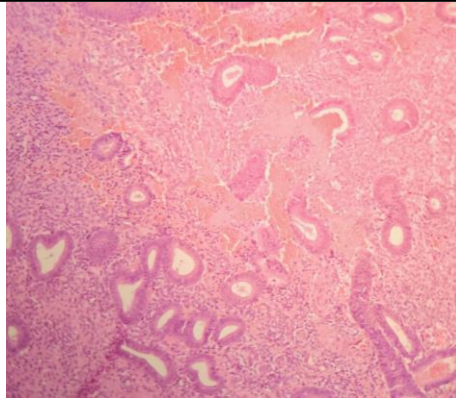
<b>Patient Name</b>	Mrs. MONITA	<b>Client Name</b>	Lifeaid Wellness Centre	<b>Specimen Received</b>	02/12/19
<b>Age/Sex</b>	22YRS/F			<b>Specimen Type</b>	Tissue
<b>Patient ID</b>	011912020210			<b>Collection Date</b>	02/12/19
<b>Specimen ID</b>	MOLQ/B-2274/19			<b>Report Date</b>	06/12/19

## **SURGICAL PATHOLOGY REPORT**

### Polyp with Endometrial biopsy

#### **DIAGNOSIS**

**ENDOMETRIAL POLYP WITH PROLIFERATIVE PHASE**



#### **SPECIMEN**

Polyp with Endometrial biopsy

#### **GROSS**

Received multiple grayish white tissue piece. E/A.


#### **Microscopy**

1. Section examined shows cuboidal lining epithelium with round to oval nucleus with endometrial glands having small round nucleus.
2. Stroma shows mononuclear inflammatory cells.
3. No granuloma seen. No malignant cells seen.

**Note :** All biopsy specimen will be stored for 15 (fifteen)days, block and slides for 5(five) years only from the time of receipt at the laboratory. No request ,for any of the above ,will be entertained after the due date.

#### **Reference**

- i) Rosai and Ackerman's Surgical Pathology.
- ii) Modern Surgical Pathology.

  
**Gulshan Yadav, MD**  
Consultant Pathologist