

Human Epidermal Growth Factor Receptor 2 Immunohistochemistry

Clinician

Clinician Name: Dr. Vinay Samuel Gaikwad
Medical Facility: Onco Care Clinic.
Pathologist: Not Provided

Test Description

Test is useful for determining overexpression of HER2 protein of gastric and esophageal adenocarcinoma in formalin-fixed, paraffin-embedded tissue sections (with reflex to FISH testing).

Clinical Information

Human epidermal growth factor receptor 2 (*HER2*), is a proto-oncogene located on chromosome 17q21 that encodes a transmembrane protein with tyrosine kinase activity, a member of the HER receptor family and is involved in signal transduction pathways, leading to cell growth and differentiation. Amplification and overexpression of the *HER2* gene have been associated with a shorter disease-free survival and shorter overall survival in gastric and gastroesophageal junction cancers, as well as breast, endometrial, and ovarian cancer.

Specimen

Sample Type: FFPE block S-6069/19 D

Site: Stomach

Pathology ID: MOLQ/IHC-56112019

Disease: Poorly Cohesive Carcinoma (Signet Ring Cell-Diffuse type)

Scoring

The scoring system is based on type and origin of tumor.

Score	Staining Pattern	Interpretation
0	No reactivity or membranous reactivity in <10% of cancer cells	Negative
1+	Faint or barely perceptible membranous reactivity in ≥10% of cancer cells; cells are reactive only in part of their membrane.	Negative
2+	Weak to moderate complete, basolateral or lateral membranous reactivity in ≥10% of tumor cells	Equivocal
3+	Strong complete, basolateral or lateral membranous reactivity in >10% of cancer cells.	Positive

Interpretation

Results are reported as positive (3+ HER2 protein expression), equivocal (2+), or negative (0 or 1+).

Equivocal (2+) cases will automatically reflex to FISH testing at an additional charge.

Methodology

Immunostaining for HER2 protein was done using PathnSitu Rabbit Anti-Human HER2 monoclonal (Clone EP3) antibody (#PR047)

References

- Rosai and Ackerman's Surgical Pathology.
- NCCN Guidelines Journal of the National Comprehensive Cancer Network 2006 4
- Ruschoff J, Dietel M, Baretton G, et al. HER2 diagnostics in gastric cancer guideline validation and development of standardized immunohistochemical testing. *Virchows Arch. Sep; 457 (3):299-307*
- Brandon S *et al.* HER2/neu Testing in Gastric Cancer by Immunohistochemistry. *Arch Pathol Lab Med* 2014 138
- Ramin Azarhoosh *et al.* HER2/neu gene amplification in gastric adenocarcinoma and its relationship with clinical and pathological findings. *J Gastrointest Oncol.* 2017 8:6

**Human Epidermal Growth Factor Receptor 2
(HER2/neu): Negative (Score 0)**

Microscopy Evaluation

HE Staining (Figure 1)

Tumor cells: 60%

Her2/neu by IHC: Score 0+

Percentage of cells with membrane staining: 07% (Figure 2)

HE Stained Section

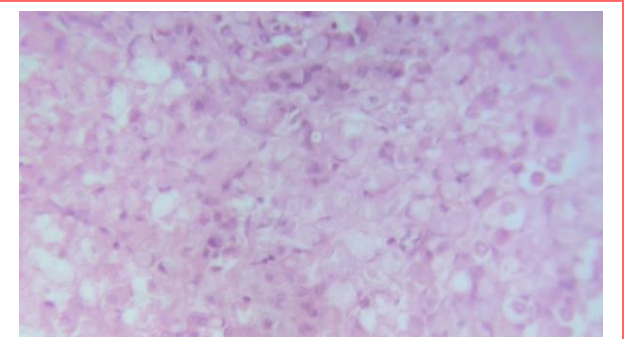


Figure 1

HER2/Neu IHC- Tumor

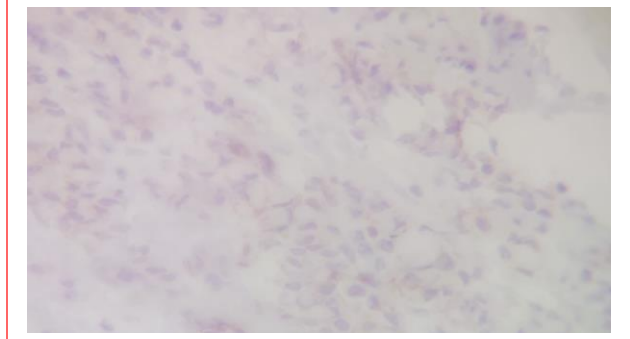


Figure 2

Reviewed By



Dr. Gulshan Yadav, MD
Head, Pathology

MolQ Laboratory (A Unit of Molecular Quest Healthcare Pvt. Ltd.)

Reference Laboratory: 28-29, Sector-18(P) | Gurgaon, Haryana, 122015 | Phone 0124 - 4307906, Fax 0124 - 4278596 | Email: contact@molq.in