

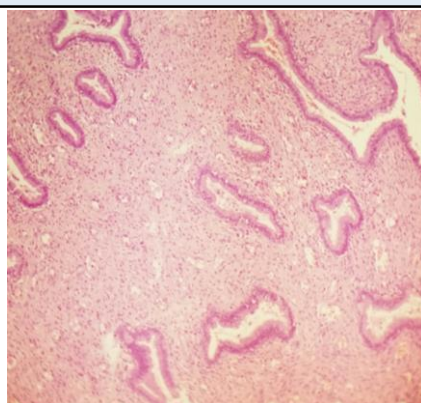
Patient Name	Mrs. SAPNA	Client Name	Pratham Diagnostic and Imaging Centre, Manesar	Specimen Received	30/11/19
Age/Sex	24YRS/F			Specimen Type	Tissue
Patient ID	011911300219			Collection Date	30/11/19
Specimen ID	MOLQ/B-2262/19			Report Date	04/12/19

SURGICAL PATHOLOGY REPORT

Left Breast Lump

DIAGNOSIS

BENIGN BREAST LESION



SPECIMEN

Left Breast Lump

GROSS

Received two greyish white tissue piece measuring 2.9x3 cm, 1x1 cm.

Microscopy

- Section examined shows ducts (few cystically dilated) with cuboidal epithelium with small round nucleus surrounded by fibro collagenous tissue.
- No granuloma seen. No malignant cells seen.

Note : All biopsy specimen will be stored for 15 (fifteen)days, block and slides for 5(five) years only from the time of receipt at the laboratory. No request ,for any of the above ,will be entertained after the due date.

Reference

- Rosai and Ackerman's Surgical Pathology.
- Modern Surgical Pathology.

Gulshan Yadav, MD
Consultant Pathologist