

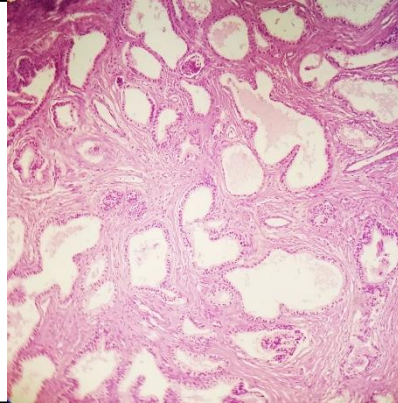
Patient Name	Mr. DALJEET SINGH	Client Name	Pushpanjali Hospital (Rewari)	Specimen Received	30/11/19
Age/Sex	60YRS/M			Specimen Type	Tissue
Patient ID	011911300214			Collection Date	30/11/19
Specimen ID	MOLQ/B-2269/19			Report Date	04/12/19

SURGICAL PATHOLOGY REPORT

TURP Chips

DIAGNOSIS

BENIGN PROSTATIC HYPERPLASIA



SPECIMEN

TURP Chips

GROSS

Received multiple grayish white tissue piece, 3x2 cm in aggregate.

Microscopy

1. Section examined shows bilayered prostatic glands with columnar lining epithelium and with small round to oval nucleus surrounded by large number of fibrocollagenous tissue and mononuclear inflammatory cell.
2. No granuloma seen. No malignant cells seen.

Note : All biopsy specimen will be stored for 15 (fifteen)days, block and slides for 5(five) years only from the time of receipt at the laboratory. No request ,for any of the above ,will be entertained after the due date.

Reference

- i) Rosai and Ackerman's Surgical Pathology.
- ii) Modern Surgical Pathology.

Gulshan Yadav, MD
Consultant Pathologist