

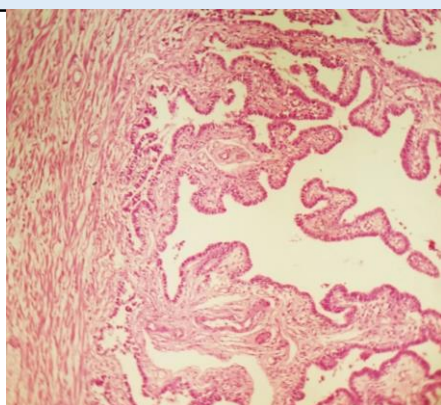
| | | | | | |
|---------------------|------------------|--------------------|------------------|--------------------------|----------|
| Patient Name | Mrs. KHUSHI | Client Name | Prakash Hospital | Specimen Received | 28/11/19 |
| Age/Sex | 23YRS/F | | | Specimen Type | Tissue |
| Patient ID | 011911280205 | | | Collection Date | 28/11/19 |
| Specimen ID | MOLQ/B-2248/19 B | | | Report Date | 04/12/19 |

SURGICAL PATHOLOGY REPORT

Tube (Right)

DIAGNOSIS

KINDLY, CO-RELATE WITH CLINICAL FINDINGS, RADIOLOGICAL FINDINGS AND B-HCG FINDINGS.



SPECIMEN

Tube (Right)

GROSS

Received 3x0.5 cm grayish white tissue piece.

Microscopy

1. Section examined shows tubal lining epithelium surrounded by fibrocollagenous tissue.
2. No villi seen.
3. No decidual cells seen.
4. No trophoblastic cells seen.

Note : All biopsy specimen will be stored for 15 (fifteen)days, block and slides for 5(five) years only from the time of receipt at the laboratory. No request ,for any of the above ,will be entertained after the due date.

Reference

- i) Rosai and Ackerman's Surgical Pathology.
- ii) Modern Surgical Pathology.

Gulshan Yadav, MD
Consultant Pathologist