

MSH2 Immunohistochemistry

Clinician

Clinician Name: Dr. Amish Vora
 Medical Facility: Hope Clinic.
 Pathologist: Not Provided

Test Description

Defects in the mismatch repair (MMR) pathway is one of the best defined molecular pathways involved in both inherited and sporadic cancer pathogenesis. Established methods to classify tumors as MMR-deficient cancers include: 1) immunohistochemistry (IHC) to measure loss of MMR protein expression; and 2) microsatellite instability analysis to identify those with a microsatellite instability-high (MSI-H) phenotype. Well established for: Hereditary Non-Polyposis Colorectal Cancer (HNPCC)-associated cancers (i.e., cancers of the colorectum, endometrium, stomach, ovaries, urinary tract, other gastrointestinal sites and brain). Loss of MMR protein expression may help to identify those with germline MMR gene mutations, which in turn may provide individuals with an opportunity for cancer prevention through colorectal, endometrial and ovarian cancer risk management options as outlined in the NCCN guidelines.

Specimen

Sample Type: FFPE block H/2987/18
Site: Gastroesophageal Junction
Pathology ID: MOLQ/IHC-53112019
Disease: Moderately Differentiated Adenocarcinoma

Interpretation

Staining must be classified based on nuclear staining intensity and distribution to generate a Combined Expression Score.

Score (Based on the percentage of positive cells)	Score 0-00% Score 1: 1-33% Positive Tumor Cells Score 2: 34-66% Positive Tumor Cells Score 3: 67-100% Positive Tumor Cells
Intensity	Score 0: Least intensity Score 1: Mild intensity Score 2: Moderate intensity Score 3: Most intensity
COMBINED EXPRESSION SCORE: (The product of intensity and staining)	Total Score 0: Negative Total Score 1-3: Weak Total Score 4-6: Moderate Total Score 7-9: Strong

For full-section slides, any value of ≤ 3 was categorized as having loss of expression, ≥ 3 was categorized as presence of expression. Immunostaining for MSH2 protein was done using PathnSitu Rabbit MSH2 monoclonal (Clone RED2) antibody (#PR055)

Note

There are two general models for how MMR proteins regulate cell-cycle checkpoints and apoptosis. The first is based on the concept of "futile repair"; that is, mismatch repair attempts to correct lesions that cannot be repaired and that during this process generate double-stranded breaks, which then trigger checkpoint and apoptosis. The second is based on the notion that mismatch repair proteins directly participate in signaling. MSH2/MSH6 heterodimer binds to mismatched bases and several other types of DNA lesions thus, they can detect lesions. When encountering mismatched bases during DNA replication, the MSH2/MSH6-complex recruits repair enzymes to correct such replication mistakes and directly participate in DNA damage signaling. This result indicates that the repair function of MSH2 can be separated from its signaling function. Although these

MSH2: Presence of Expression

Microscopy Evaluation

HE Staining (Figure 1)

MLH2 by IHC: (Figure 2)

Percentage of cells nuclear staining: 30% (Score 1)
 Intensity: (Score 3)

Combined Expression Score: 3 (Weak)

MSH2 IHC - Tumor

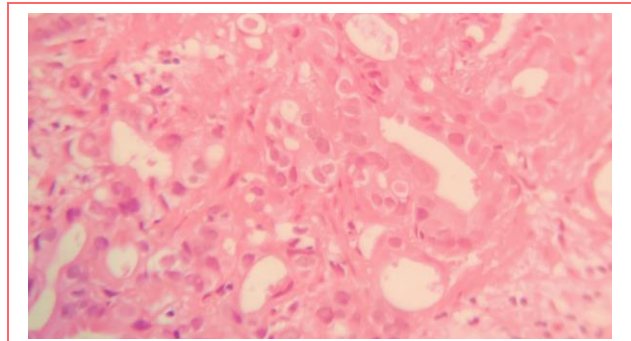


Figure 1

MSH2 IHC- Tumor Cells

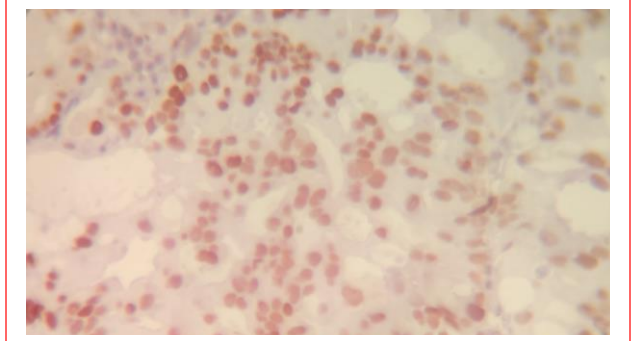


Figure 2

Reviewed By



Dr. Gulshan Yadav, MD
 Head, Pathology

two lines of evidence indicate mismatch repair proteins to participate in DNA damage signaling, they certainly have not ruled out a role for futile repair in the induction of apoptosis.

References

1. Uncertainty in the Utility of Immunohistochemistry in Mismatch Repair Protein Expression in Epithelial Ovarian Cancer. D Coppola *et al.* *Anticancer Res.* 2012 Nov; 32(11).
2. Association Between IHC and MSI Testing to Identify Mismatch Repair-Deficient Patients with Ovarian Cancer. Ji-Hyun Lee *et al.* *Genet Test Mol Biomarkers.* 2014 Apr 1; 18(4).
3. Colorectal Carcinomas With Isolated Loss of PMS2 Staining by Immunohistochemistry Lindsay Alpert *et al.* *Archives of Pathology & Laboratory Medicine* 2018 142:4.
4. Germline mutations in PMS2 and MLH1 in individuals with solitary loss of PMS2 expression in colorectal carcinomas from the Colon Cancer Family Registry Cohort Christophe Rosty *et al.* *BMJ Open.* 2016; 6(2): e010293