

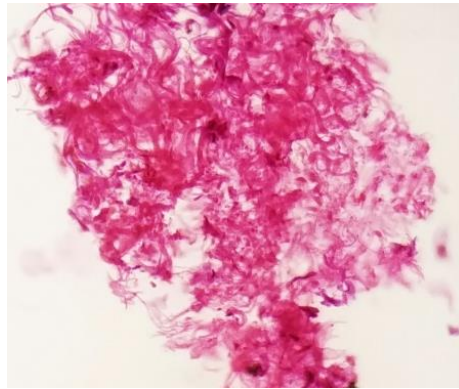
Patient Name	Mr. DILEEP KUMAR	Client Name	Uttam Diagnostics, Agra	Specimen Received	30/11/19
Age/Sex	22YRS/M			Specimen Type	Tissue
Patient ID	011911300010			Collection Date	30/11/19
Specimen ID	MOLQ/B-2255/19			Report Date	03/12/19

SURGICAL PATHOLOGY REPORT

Chest sholder (Right side)

DIAGNOSIS

BENIGN EPIDERMAL CYST.



SPECIMEN

Chest sholder (Right side)

GROSS

Received 3x2cm grayish white tissue piece, cut section shows necrotic material .

Microscopy


Section examined shows a nucleated squamous epithelial cells with squamous lining epithelium keratin .

No granuloma seen. No malignant cells seen.

Note : All biopsy specimen will be stored for 15 (fifteen)days, block and slides for 5(five) years only from the time of receipt at the laboratory. No request ,for any of the above ,will be entertained after the due date.

Reference

- i) Rosai and Ackerman's Surgical Pathology.
- ii) Modern Surgical Pathology.


Gulshan Yadav, MD
Consultant Pathologist