

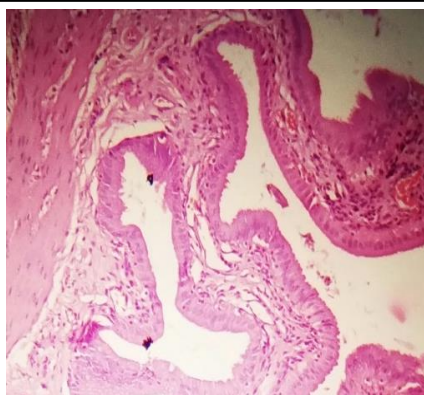
Patient Name	Ms. BASANTI DEVI	Client Name	Shri Balaji Multispeciality Hospital-Gurgaon	Specimen Received	26/11/19
Age/Sex	61YRS/F			Specimen Type	Tissue
Patient ID	011911260152			Collection Date	26/11/19
Specimen ID	MOLQ/B-2229/19			Report Date	28/11/19

SURGICAL PATHOLOGY REPORT

Gall Bladder

DIAGNOSIS

CHOLECYSTITIS



SPECIMEN

Gall Bladder

GROSS

Received 5.4x2.6cm long gall bladder. Cut section shows no stones. wall thickness 0.3mm

Microscopy

Section examined shows ulcerative mucosa and Rokitansky-Aschoff sinus (irregularly shaped tubular structures lined by cuboidal lining epithelium with round to oval nucleus) with fibro collagenous tissue and inflammatory cells (lymphocytes).

Note : All biopsy specimen will be stored for 15 (fifteen) days, block and slides for 5 (five) years only from the time of receipt at the laboratory. No request, for any of the above, will be entertained after the due date.

Reference

- i) Rosai and Ackerman's Surgical Pathology.
- ii) Modern Surgical Pathology.

Gulshan Yadav, MD
Consultant Pathologist