

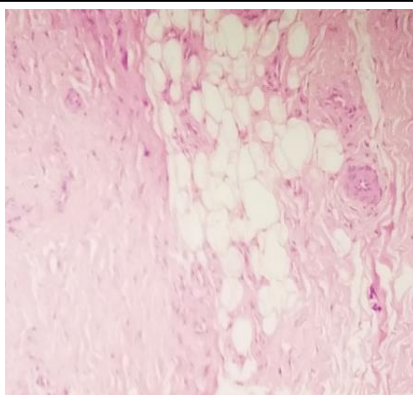
Patient Name	Mr. MANDEEP	Client Name	Kamal Hospital and Maternity Centre	Specimen Received	26/11/19
Age/Sex	13YRS/M			Specimen Type	Tissue
Patient ID	011911260103			Collection Date	26/11/19
Specimen ID	MOLQ/B-2228/19			Report Date	28/11/19

SURGICAL PATHOLOGY REPORT

Left hand dorsal(Tenosynovitis)

DIAGNOSIS

MILD INFLAMMATION



SPECIMEN

Left hand dorsal(Tenosynovitis)

GROSS

Received multiple grayish white tissue piece, 1x0.9 cm in aggregate.

Microscopy

Section examined shows fibrocollagenous tissue with oval to spindle shaped nucleus with mature adipose cells and nerve bundle ,blood vessels with mononuclear inflammatory cells (Histiocytes and Lymphocytes)

Note : All biopsy specimen will be stored for 15 (fifteen)days, block and slides for 5(five) years only from the time of receipt at the laboratory. No request ,for any of the above ,will be entertained after the due date.

Reference

- i) Rosai and Ackerman's Surgical Pathology.
- ii) Modern Surgical Pathology.

Gulshan Yadav, MD
Consultant Pathologist