

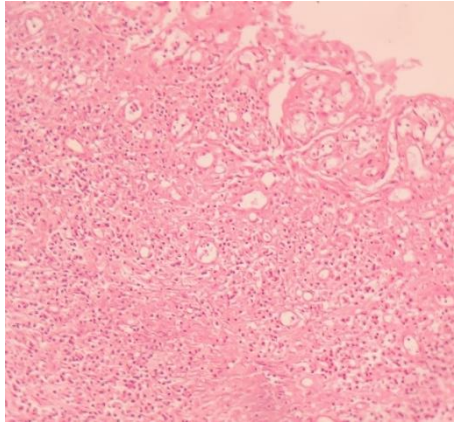
<b>Patient Name</b>	Mr. ALHARBI SALEH ALIM	<b>Specimen Received</b>	25-Nov-2019
<b>Age/Sex</b>	56 Years/Male	<b>Specimen Type</b>	Tissue
<b>Patient ID</b>	011911250042	<b>Collection Date</b>	25-Nov-2019
<b>Specimen ID</b>	MOLQ/B-2218/19	<b>Report Date</b>	29-Nov-2019

## SURGICAL PATHOLOGY REPORT

Anterior Maxilla (irt 11,12,21,22)

### DIAGNOSIS

**BENIGN INFLAMMATORY CYSTIC LESION  
(SUGGESTIVE OF RESIDUAL CYST)**



#### SPECIMEN

Anterior Maxilla (irt 11,12,21,22)

#### GROSS

Received three greyish white tissue pieces, first measuring 2.8x2.6 cm cystic tissue piece, firm in consistency and 1x0.5 cm, 0.5x0.5 cm.

#### Microscopy

Section examined shows proliferating squamous lining epithelium of varying thickness with round to oval nucleus. Deeper tissue shows dense and diffuse inflammatory cells chiefly composed of lymphocytes and plasma cells, fibrocollagenous tissue and blood vessels. No granuloma seen. No malignaat cells seen.

**Note :** All biopsy specimen will be stored for 15 (fifteen)days, block and slides for 5(five) years only from the time of receipt at the laboratory. No request ,for any of the above ,will be entertained after the due date.

#### Reference

- i) Rosai and Ackerman's Surgical Pathology.
- ii) Modern Surgical Pathology.
- iii) Shafer's, 7<sup>th</sup> edition

**Tina Bhardwaj, MDS**  
Consultant Oral Pathologist

**Gulshan Yadav, MD**  
Consultant Pathologist