

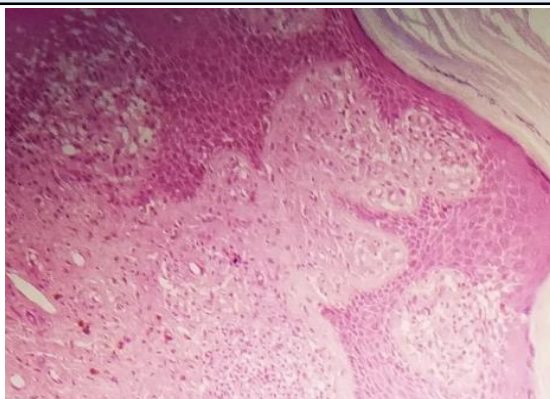
Patient Name	Mr. MOHD ASHRAF	Client Name	Apollo Laboratories CC, Jammu & Kashmir	Specimen Received	24/11/19
Age/Sex	40YRS/M			Specimen Type	Tissue
Patient ID	011911240293			Collection Date	24/11/19
Specimen ID	MOLQ/B-2217/19			Report Date	27/11/19

SURGICAL PATHOLOGY REPORT

Left Leg (Ulcer)

DIAGNOSIS

CHRONIC INFLAMMATION



SPECIMEN

Left Leg (Ulcer)

GROSS

Received 1x1 cm greyish white tissue piece with skin attached.

Microscopy

Section examined shows squamous lining epithelium with hyperkeratosis and parakeratosis. Deeper tissue shows fibrocollagenous tissue and blood vessels with mono nuclear inflammatory cells.

No granuloma seen.

Note : All biopsy specimen will be stored for 15 (fifteen)days, block and slides for 5(five) years only from the time of receipt at the laboratory. No request ,for any of the above ,will be entertained after the due date.

Reference

- i) Rosai and Ackerman's Surgical Pathology.
- ii) Modern Surgical Pathology.

Gulshan Yadav, MD
Consultant Pathologist