

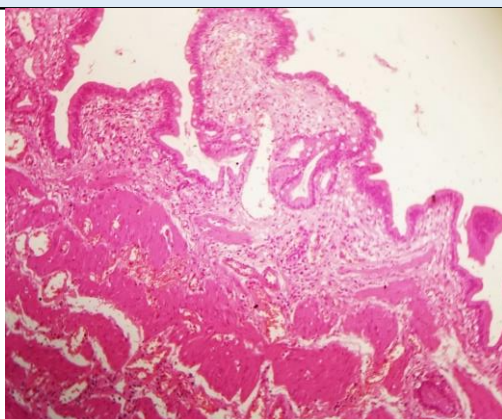
Patient Name	Ms. HASEENA	Client Name	Faith Clinical Laboratory	Specimen Received	23/11/19
Age/Sex	38 YRS/F		Jammu & Kashmir	Specimen Type	Tissue
Patient ID	011911220287			Collection Date	23/11/19
Specimen ID	MOLQ/B-2207/19			Report Date	26/11/19

SURGICAL PATHOLOGY REPORT

Gall Bladder

DIAGNOSIS

CHOLECYSTITIS AND CHOLELITHIASIS.



SPECIMEN

Gall Bladder

GROSS

Received 7x2.8cm long gall bladder. Cut section shows stones.

Microscopy

1. Section examined shows ulcerative mucosa and rokitansky aschoff sinus (irregularly shaped tubular structures lined by cuboidal lining epithelium with round to oval nucleus) with fibro collagenous tissue and inflammatory cells (lymphocytes).

Note : All biopsy specimen will be stored for 15 (fifteen)days, block and slides for 5(five) years only from the time of receipt at the laboratory. No request ,for any of the above ,will be entertained after the due date.

Reference

- i) Rosai and Ackerman's Surgical Pathology.
- ii) Modern Surgical Pathology.

Gulshan Yadav, MD
Consultant Pathologist